Uniwersytet Medyczny w Łodzi
Katedra Kosmetologii
Zakład Kosmetologii i Dermatologii Estetycznej

Kamila Zduńska-Pęciak

Ocena porównawcza wpływu kwasu ferulowego oraz kwasu ferulowego wraz z mikronakłuwaniem na wybrane parametry skóry

Comparative assessment of the effect of ferulic acid and ferulic acid with microneedling on selected skin parameters

Rozprawa na stopień doktora nauk farmaceutycznych

Promotor
Prof. dr hab. n.med. Helena Rotsztejn

ŁÓDŹ 2022

Serdecznie dziękuję

Pani prof. dr hab. n .med. Helenie Rotsztejn

za opiekę naukową, okazaną życzliwość, wnikliwe uwagi

oraz wszelką pomoc i poświęcony czas

w trakcie realizacji badań i redagowania pracy.

Dziękuję mężowi Radkowi za miłość, wsparcie, cierpliwość, wyrozumiałość i niegasnącą we mnie wiarę.

Dziękuję Rodzicom za przykład, motywację, przekazanie ambicji i zadaniowości, duchowe wsparcie, kojące ciepło domowego ogniska.

Tę pracę dedykuję mojej ukochanej córeczce Hani.

Spełniłaś moje największe marzenie. Drugie właśnie się spełnia.

1 WSTĘP ... 3
1.1 Wprowadzenie ... 3
1.2 Starzenie się skóry ... 4
1.3 Kwas ferulowy ... 7
1.4 Mikronakłuwanie skóry ... 17
2 CZĘŚĆ BADAWCZA ... 20
2.1 Założenia i cele pracy ... 20
2.2 Materiał i metody ... 21
2.2.1 Charakterystyka grupy badanej ... 21
2.2.2 Procedury zabiegowe ... 26
2.2.3 Ocena aparaturowa ... 29
2.2.4 Dokumentacja fotograficzna ... 34
2.3 Wyniki ... 36
2.4 Dyskusja ... 60
2.5 Wnioski ... 63
3 STRESZCZENIE ... 64
4 STRESZCZENIE W JĘZYKU ANGIELSKIM ... 66
5 PIŚMIENNICTWO ... 68
6 SPIS RYCIN I TABEL ... 78
7 WYKAZ SKRÓTÓW ... 79
8 ZAŁĄCZNIKI ... 82
8.1 Oświadczenia współautorów ... 82
8.2 Zgoda Komisji Bioetyki ... 91
8.3 Formularz świadomej zgody ... 93
8.4 Publikacje poglądowe ... 94

1 WSTĘP

1.1 Wprowadzenie

Prace nad wydłużeniem i poprawą jakości życia ludzkiego są przedmiotem badań wielu ośrodków na całym świecie. Dotyczą one zagadnień z różnorodnych dziedzin, obejmujących zarówno zdrowie psychiczne, jak i fizjologię i zdrowie w ujęciu fizycznego dobrostanu. Obecne tempo życia, stres, zanieczyszczenie środowiska, nieprawidłowo zbilansowana dieta – to czynniki, które mogą przyczyniać się do szybszego niż w ubiegłych latach, powstawania i rozwoju tzw. chorób cywilizacyjnych. Dlatego tak ważne wydaje się zachowanie spójności i wzajemne wspieranie się różnych dziedzin nauki, jako że odkrycia jednej z nich, mogą zostać wykorzystane w innych obszarach wiedzy. Dobrym przykładem może być wzrastające zainteresowanie związkami bioaktywnymi, wykazującymi prozdrowotne właściwości i wykorzystanie ich, zarówno przez wytwórców żywności w przemyśle spożywczym, wytwórców leków w przemyśle farmaceutycznym, jak i wytwórców kosmetyków w przemyśle chemicznym.

Za związki bioaktywne uważa się wszelkie komponenty, zawierające substancje lecznicze i odżywcze, które zazwyczaj występują w roślinach w małych ilościach. Mogą one wzmacniać, osłabiać lub modyfikować funkcje fizjologiczne i metaboliczne organizmu. Jedną z dużych grup związków bioaktywnych, będącą przedmiotem zainteresowania wielu badaczy, są związki polifenolowe, a wśród nich flawonoidy i kwasy fenolowe. Posiadają one silne właściwości antyoksydacyjne, wywierając prozdrowotny wpływ na organizm ludzki i chroniąc go przed stresem oksydacyjnym. Uczestniczą w procesach naprawczych i adaptacyjnych ustroju, działając profilaktycznie, a niekiedy nawet leczniczo w różnych chorobach [1].

Kwasy fenolowe i ich pochodne stanowią bioaktywne komponenty żywności, często poprawiając jej jakość, wzbogacając smak i zapach. Ich wielokierunkowe działanie wykorzystuje się także w przemyśle farmaceutycznym i kosmetycznym. Związki te wykazują wysoką skuteczność m.in. w niwelowaniu defektów skórnych. Obiektywna ocena działania preparatów kosmetycznych, zawierających kwasy fenolowe i ich pochodne, stanowi istotne źródło wiedzy na temat celowości ich stosowania, możliwości uzyskiwanych efektów oraz ewentualnych skutków ubocznych.

1.2 Starzenie się skóry

Starzenie się skóry możemy przypisać wielu czynnikom, spośród których wyróżniamy 2 główne typy: wewnątrzpochodne oraz zewnątrzpochodne. Na pierwsze z nich nie mamy wpływu, stanowią naturalny, biologiczny nieunikniony proces i są związane z tzw. „bagażem genetycznym'' danej osoby. Starzenie się skóry zależne od czynników wewnątrzpochodnych to tzw. starzenie chronologiczne. Do czynników zewnątrzpochodnych zaliczamy m.in. stosowanie używek (tytoń, alkohol, narkotyki), nieprawidłową dietę, zanieczyszczenie powietrza oraz promieniowanie UV. Chroniczna, nadmierna ekspozycja na światło słoneczne przyczynia się do powstania szeregu zmian obejmujących zarówno naskórek jak i skórę właściwą, określanych mianem fotostarzenia [2, 3].

Fotostarzenie. W fotostarzeniu skóry, największą rolę odgrywa promieniowanie UVA (320-400 nm) oraz promieniowanie UVB (290-320 nm) przy czym promieniowanie UVA stanowi 96-99% całego UVR docierającego do ziemi [4]. Promieniowanie UVB w znacznym stopniu pochłaniane jest przez sam naskórek, docierając maksymalnie do jego warstwy podstawnej, stąd wpływa głównie na barierę hydrolipidową, keratynocyty oraz komórki Langerhansa. Powoduje tzw. reakcje natychmiastowe, do których należą: oparzenia słoneczne, rumień, immunosupresja. Promieniowanie UVA przenika głębiej - docierając do struktur w obrębie skóry właściwej takich jak m.in.: fibroblasty, włókna kolagenowe i elastynowe, komórki tuczne, granulocyty [5]. Odpowiada za reakcje opóźnione w tym: procesy alergiczne, przebarwienia. Oba typy promieniowania (zarówno UVA, jak i UVB) mogą przyczyniać się do powstawania nowotworów skóry [6].

Do klinicznych objawów fotostarzenia należą:
- atroficzny, suchy, łuszczący się naskórek,
- zmarszczki i bruzdy (zwykle głębsze niż przy starzeniu endogennym),
- liczne zmiany barwnikowe (piegi, plamy soczewicowate, plamiste przebarwienia),
- znaczna utrata elastyczności skóry,
- zmiany przerostowe (rogowacenie słoneczne, hiperplazja gruczołów łojowych)
- prosaki, zaskórniki,
- teleangiektazje.

Zmiany w obrębie naskórka. Zmiany morfologiczne w naskórku, po nadmiernej ekspozycji na promieniowanie UV, dotyczą przede wszystkim jego złuszczania, nadmiernego rogowacenia, nieprawidłowej proliferacji i różnicowania komórek. W skórze poddanej ekspozycji na promieniowanie słoneczne dochodzi do wydzielania wielu cytokin prozapalnych tj.: IL-1 (Interleukina 1), IL-6 (Interleukina 6), IL-8 (Interleukina 8), TNF-α (ang.Tumor Necrosis Factor α - czynnik martwicy nowotworu α), co przyczynia się m.in. do nadmiernej hiperplazji i złuszczania naskórka. Cytokiny inicjują także odpowiedź zapalną objawiającą się rumieniem (za najbardziej rumieniotwórcze uznaje się promieniowanie UVB) [7, 8]. Postępująca pod wpływem UV oksydacja lipidów i białek warstwy rogowej naskórka, prowadzi do zmiany składu płaszcza lipidowego (zmniejsza się zawartość ceramidów, steroli i kwasów tłuszczowych - ɣ-linolenowego i palmitynowego), a w następstwie dochodzi do zaburzenia funkcjonowania bariery naskórkowej i zwiększenia transepidermalnej utraty wody (transepidermal water loss - TEWL) [9].

Komórkami naskórka, w największym stopniu narażonymi na nadmierną ekspozycję słoneczną są keratynocyty, melanocyty i komórki Langerhansa (KL). Pod wpływem promieniowania UVR może dochodzić do powstawania atypii komórek, utraty polarności, uszkodzeń DNA. Nawet niewielkie dawki UV prowadzą do utraty wypustek dendrytycznych KL, zmniejszenia zdolności prezentacji antygenów limfocytom T, uszkodzenia DNA, a w konsekwencji upośledzenia ich czynności, co może wywołać stan immunosupresji oraz tolerancji immunologicznej (ang. bystander suppression) [10, 11]. Przy nadmiernej ekspozycji na promieniowanie UV może dochodzić do uszkodzenia, zwiększonej proliferacji, hiperplazji i dysplazji melanocytów, co z kolei przyczynia się do powstawania zaburzeń barwnikowych o różnej etiologii (zarówno na poziomie biochemicznych zaburzeń syntezy melaniny, zmiany ilości i zaburzeń formowania melanocytów, jak i dojrzewania i transportu melanosomów) [12, 13].

Zaburzenie funkcjonowania naskórka, poddanego nadmiernej ekspozycji na promieniowanie UVR, jest związane także ze zmianami w obrębie połączenia skórno-naskórkowego (ang. dermal-epidermal junction - DEJ). Ulega ono wygładzeniu i ścieńczeniu, co znacznie zmniejsza powierzchnię styku naskórka i skóry właściwej,

ograniczając przenikanie substancji odżywczych. W konsekwencji naskórek staje się mniej odporny na niekorzystne wpływy środowiska [14].

Zmiany w obrębie skóry właściwej. Jedną z bardziej charakterystycznych zmian w skórze fotostarzejącej się, jest zjawisko elastozy. Nadmiernie pogrubiałe, nieprawidłowo ułożone włókna sprężyste tracą swoje właściwości, co przejawia się znaczną utratą elastyczności skóry. Elastyna w wyniku uszkodzeń cechuje się zmniejszoną ilością reszt cukrowych, a zwiększoną – polarnych aminokwasów [15]. Pod wpływem UVB dochodzi do wzrostu ekspresji mRNA tropoelastyny w fibroblastach, a w następstwie - kumulacji i zwiększenia ilości amorficznej elastyny. Nieprawidłowe włókna zaczynają przyłączać cząsteczki lizozymu- enzymu hamującego proteolityczną aktywność elastazy leukocytowej (ang. human leukocyte elastase - HLE), co stanowi mechanizm obronny przeciwko naturalnemu rozkładowi elastyny [16, 17].

W procesie fotostarzenia zmianom ulega także ilość oraz sposób ułożenia włókien kolagenowych, największe obserwuje się w obrębie kolagenu typu I, a jego ubytek jest skorelowany z zakresem uszkodzenia przez światło słoneczne [18, 19]. Pod wpływem UV pobudzane są, rozkładające kolagen, metaloproteinazy (ang. matrix metalloproteinases, MMP) m.in. kolagenaza, żelatynaza, stromielizyna. Ekspozycja na UV powoduje wzrost ilości czynników transkrypcyjnych, wzmagających syntezę białka AP-1, uaktywniającego geny mataloproteinaz. Wzmożona produkcja MMP powoduje także proteolizę białek macierzy zewnątrzkomórkowej.

Istotę podstawową tkanki łącznej (ang. etracellular matrix - ECM), z której zbudowana jest skóra właściwa, tworzą w dużej mierze glikozaminoglikany (GAG). Największe zmiany ilościowe dotyczą kwasu hialuronowego (ang. hyaluronic acid - HA) oraz siarczanu chondroityny. W wyniku działania światła słonecznego dochodzi do spadku ilość HA i wzrostu siarczanu chondroityny, co odzwierciedla proporcje tych glikozaminoglikanów w bliźnie [18, 20].

1.3 Kwas ferulowy

Właściwości i występowanie. Kwas ferulowy (kwas 4-hydroksy-3-metoksycynamonowy) jest organicznym związkiem chemicznym, należącym do polifenoli - dużej grupy bioaktywnych związków występujących naturalnie w roślinach. Stanowi hydroksylową pochodną kwasu cynamonowego, należącego do kwasów fenolowych [21]. Pierwszy raz kwas ferulowy (ang. Ferulic Acid - FA) (Ryc. 1.) został wyizolowany z Ferula foetida w celu określenia jego struktury. W 1925 roku został po raz pierwszy zsyntetyzowany, a struktura chemiczna została potwierdzona za pomocą technik spektroskopowych. Jego wzór cząsteczkowy to C10H10O4, a masa cząsteczkowa wynosi 194,18 g/mol [22]. Ma postać jasnożółtego krystalicznego proszku, rozpuszczającego się dobrze w wodzie (0,78 g/dm^3 w T=20°C) i etanolu. Temperatura topnienia wynosi 168-172°C.

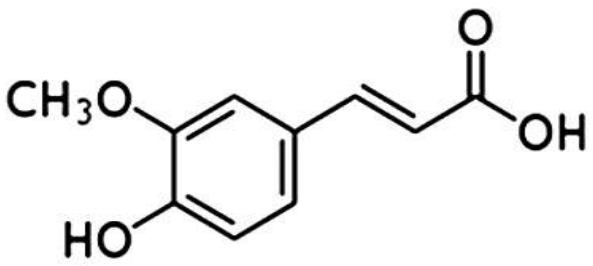

Ryc. 1. *Wzór strukturalny kwasu ferulowego [23]*

Głównymi źródłami kwasu ferulowego są owoce, warzywa, zboża (pszenica, jęczmień, owies, żyto) oraz zioła lecznicze (szałwia, lubczyk). Znajduje się on również w nasionach i korze drzew iglastych [24, 25]. Szczególnie bogate w FA są ziarniaki zbóż, w których w formie związanej z arabinoksylanami, pełni funkcję ochraniającą lipidy, zawarte w ziarnie, przed utlenianiem [26]. Średnią zawartość FA w poszczególnych produktach roślinnych przedstawiono w Tabeli 1 [27].

Tab. 1. *Zawartość kwasu ferulowego w wybranych produktach spożywczych pochodzenia roślinnego*

Źródło	Zawartość kwasu ferulowego (mg/0,1 kg)
Pędy bambusa	243.6
Bakłażan	7.3–35
Burak czerwony	25
Soja	12
Szpinak	7.4
Pomidor	0.29–6
Rzodkiewka	4.6
Brokuł	4.1
Marchew	1.2–2.8
Kapusta pekińska	1.4
Zielona fasola	1.2
Awokado	1.1
Grejpfrut	0.25–2.7
Pomarańcza	9.2–9.9
Banan	5.4
Jagody	10.7–11.6
Rabarbar	2
Śliwka	1.47
Jabłko	8.2
Pulpa buraczana	800
Popcorn	313
Chleb pełnoziarnisty	54
Pełnoziarniste płatki owsiane	25–52
Kukurydza	42
Brązowy ryż	24
Kawa	9.1–14.3
Makaron	12

Biosynteza kwasu ferulowego. Kwas ferulowy powstaje w roślinach na drodze przemian metabolicznych kwasu szikimowego, będącego prekursorem aminokwasów aromatycznych (fenyloalaniny lub tyrozyny), które w procesie deaminacji zostają przekształcone do kwasu cynamonowego, a ten do ferulowego, kawowego lub p-kumarowego [28]. Szlak syntezy kwasów hydroksycynamonowych w roślinach przedstawia Rycina 2 [29].

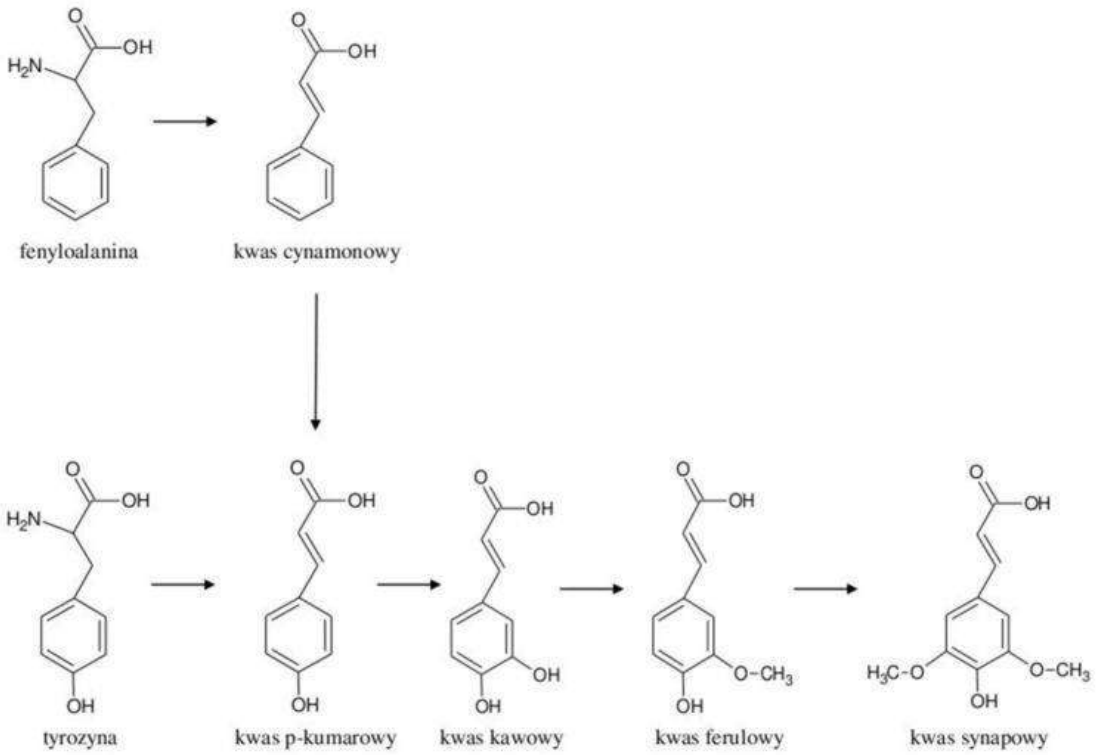

Ryc. 2. *Szlak syntezy kwasów hydroksycynamonowych*

Kwas ferulowy może powstawać także jako metabolit pośredni mikrobiologicznego rozkładu ligniny, znajdującej się w ścianach komórkowych roślin, na skutek przemian eugenolu do alkoholu, a następnie aldehydu koniferylowego. Aldehyd przy udziale dehydrogenazy aldehydu koniferylowego, zostaje przekształcony do kwasu ferulowego. Dalsza biotransformacja, z udziałem mikroorganizmów *Pseudomonas fluorescens,* prowadzi do wytworzenia kwasu wanilinowego - podstawowego substratu do produkcji szeroko stosowanej w przemyśle spożywczym waniliny [30].

Aktywność antyoksydacyjna. Samorzutne utlenianie biomolekuł w ludzkim organizmie jest procesem fizjologicznym i dość powolnym. Powstające przy okazji procesów przemiany materii wolne rodniki są neutralizowane i/lub likwidowane w reakcjach enzymatycznych i nieenzymatycznych oraz przy udziale endo- i egzogennych przeciwutleniaczy. Zachwianie równowagi pomiędzy stałą produkcją reaktywnych form tlenu, a ich likwidacją, prowadzi do powstawania tzw. szoku tlenowego, generując liczne nieprawidłowości w układach biologicznych. Autooksydacja powoduje zmiany struktury węglowodanów, białek, kwasów nukleinowych, fosfolipidów, prowadząc do szeregu niekorzystnych zmian w organizmie, w tym rozwoju wielu chorób, między innymi neurodegeneracyjnych [31, 33].

Autooksydacja z udziałem wolnych rodników to reakcja łańcuchowa, przebiegająca według trójetapowego mechanizmu obejmującego: inicjację, propagację, terminację. Związki fenolowe, w tym kwas ferulowy należą do tzw. antyoksydantów interwentywnych (ang. *chain-breaking antioxidants*) - substancji hamujących peroksydację na etapie propagacji. Związki te przerywają zapoczątkowany już łańcuch kinetyczny autooksydacji [31]. Interwerentywne antyoksydanty fenolowe (ArOH) reagują z rodnikiem nadtlenkowym ($ROO^{\cdot}$) zgodnie z reakcją przedstawioną za pomocą równania:

$$ROO^{\cdot} + ArOH \rightarrow ROOH + ArO^{\cdot}$$

W obecności pochodnych fenolowych (ArOH) rodniki nadtlenkowe, powstające w etapie propagacji, są przekształcane w dezaktywowane produkty nierodnikowe [32, 33].

Produktem reakcji kwasu ferulowego z wolnym rodnikiem tlenowym jest stabilny rodnik fenoksylowy (Ryc. 3.) [32, 34]. Neutralizacja RO˙ odbywa się poprzez przeniesienie atomu wodoru od fenolu do rodnika.

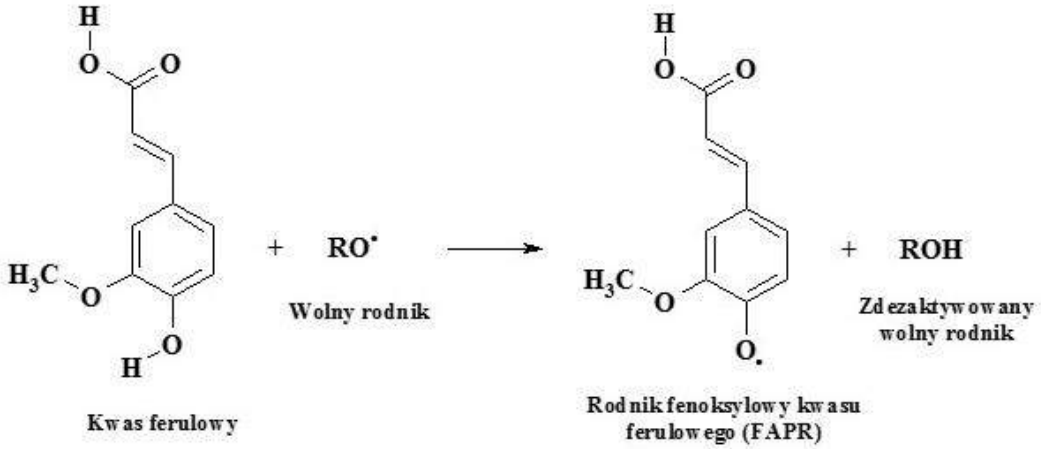

Ryc. 3. *Równanie reakcji powstawania rodnika fenoksylowego [amic a]*

W zależności od szeregu czynników, warunkujących właściwości przeciwutleniające antyoksydantów fenolowych (m.in.: siły wiązania O-H w ArOH, hydrofilowości/lipofilowości ArOH), reakcja związku fenolowego (ArOH) z wolnym rodnikiem ($RO^{\cdot}$) może zachodzić według jednego z 4 mechanizmów [35, 36, 37]:

- **HAT (ang. *Hydrogen Atom Transfer*)** - jednoetapowego przeniesienia atomu wodoru od pochodnej fenolowej do rodnika,
- **SPLET (ang. *Sequential Proton Loss Electron Transfer*)** - mechanizmu obejmującego dysocjację pochodnej fenolowej i przeniesienie elektronu z anionu fenolanowego
do rodnika,
- **PCET (ang. *Proton-Coupled Electron Transfer*)** - przeniesienia protonu odbywającego się równocześnie z transferem elektronu,
- **ET-PT (ang. *Electron Transfer - Proton Transfer*)** - przeniesienia protonu poprzedzonego przeniesieniem elektronu.

Niezależnie od mechanizmu pojedynczej reakcji ($1H^{+}/1e^{-}$), produkty końcowe są takie same, tj. nieaktywny wolny rodnik, zawierający grupę hydroksylową (ROH) i rodnik fenoksylowy (aryloksylowy) ($ArO^{\cdot}$) [36, 38].

Poza przerywaniem już zapoczątkowanych reakcji wolnorodnikowych, kwas ferulowy i jego pochodne jako tzw. przeciwutleniacze wtórne, wykazują zdolność do chelatowania jonów metali przejściowych (głównie miedzi i żelaza) [39, 40]. Metale przejściowe odgrywają istotną rolę w generowaniu wolnych rodników tlenowych w organizmach żywych. Układ jonów żelaza Fe^{2+}/Fe^{3+} stanowi katalizator procesów przekształcania nadtlenku wodoru z wytworzeniem wyjątkowo reaktywnych rodników hydroksylowych (reakcja Fentona), a także anionów ponadtlenkowych (reakcja Habera-Weissa) [41, 42]. Produkcja tych rodników może prowadzić do peroksydacji lipidów, modyfikacji białek, uszkodzeń w obrębie DNA komórek. Czynniki chelatujące mogą inaktywować jony metali i potencjalnie hamować zależne od nich reakcje [43]. Wykazano, że kwasy hydroksycynamonowe i ich pochodne (w tym kwas ferulowy) są lepszymi ligandami dla jonów żelaza niż kwasy hydroksybenzoesowe, ze względu na obecność grupy etylenowej pomiędzy pierścieniem benzenowym, a grupą karboksylową. Ma ona wpływ zarówno na zdolność chelatowania jonów metali, jak i na aktywność redukującą wolne rodniki tlenowe [44].

Zastosowanie

Medycyna. Kwasy fenolowe, w tym kwas ferulowy odgrywają szczególną rolę w zapobieganiu i leczeniu chorób, których przyczyn upatruje się w utleniającym działaniu wolnych rodników. Są to: cukrzyca, astma oskrzelowa, zakażenia wirusowe, choroba Parkinsona, choroba Alzheimera [45]. Poza właściwościami antyoksydacyjnymi, kwasy fenolowe wykazują również wysoką aktywność przeciwzapalną, co stanowi kolejny argument, przemawiający za wykorzystaniem ich w przypadku chorób układu nerwowego [46, 47].

Spożywanie produktów bogatych w kwas ferulowy jest bardzo korzystne dla osób chorujących na cukrzycę. FA ma działanie obniżające poziom glukozy we krwi, przyczynia się do spadku zawartości cholesterolu, kwasu moczowego, kreatyniny, triglicerydów, jednocześnie powodując wzrost poziomu insuliny we krwi. Działanie hipoglikemiczne ekstraktów fenolowych związane jest także z ograniczeniem absorpcji węglowodanów w jelicie oraz poprawą funkcjonowania komórek beta trzustki [48, 49]. Kwas ferulowy określany jest mianem inhibitora chorób nowotworowych, wykazując wysoką aktywność przeciwutleniającą w stosunku do wolnych rodników [26]. Inne jego pochodne, takie jak 8,5-dihydrobenzenofurany, działają cytotoksycznie na komórki białaczki, raka sutka i okrężnicy, a kurkumina i kwas rozmarynowy posiadają dodatkowo właściwości przeciwzapalne [50, 51].

Choroby układu sercowo-naczyniowego stanowią kolejną grupę, w której kwasy fenolowe wykazują szczególnie korzystne działanie. Badania dowodzą, że dieta bogata w związki polifenolowe zmniejsza ryzyko zachorowalności, a nawet umieralności na choroby serca. Ma to związek ze zdolnością fenolokwasów do ochrony frakcji LDL cholesterolu przed utlenianiem, hamowania miażdżycy, regulacji stężenia lipoprotein, hamowania agregacji płytek krwi [24, 52]. Ze względu na działanie żółciopędne, FA wykorzystywany jest także w schorzeniach układu pokarmowego. Właściwości przeciwbakteryjne (szczególnie w stosunku do Gram-dodatnich bakterii – Bacillus sp.) i przeciwzapalne dają możliwość szerokiego zastosowania FA w medycynie [53].

Przemysł spożywczy. Kwasy fenolowe, w tym kwas ferulowy, kawowy, galusowy mogą być określane mianem tzw. nutraceutyków - substancji wzbogacających o działaniu prozdrowotnym. Poza działaniem profilaktycznym i naprawczym na ustrój, wywierają korzystny wpływ na żywność, poprawiając jej jakość, nadając cechy sensoryczne takie jak: smak, barwa, zapach oraz chroniąc przez zbyt szybkim popsuciem [54]. Wykazano, że kwas ferulowy neutralizuje wolne rodniki efektywniej niż powszechnie stosowane konserwanty takie jak: butylohydroksytoluen (BHT) i butylohydroksyanizol (BHA) [55, 56]. Efektywność dodatków do żywności, takich jak FA, zależy w dużej mierze od ich stabilności termicznej i odporności na odparowanie i degradację, w zakresie stosowanych w przemyśle spożywczym temperatur. Wykazano, że długołańcuchowe estry kwasu ferulowego, szczególnie ferulan oktadecylu są znacznie bardziej odporne na działanie wysokich temperatur niż sam FA oraz stosowane przeciwutleniacze syntetyczne. Kwasy fenolowe mogą zatem stanowić dobry dodatek szczególnie do roślinnych olejów smażalniczych. Charakter hydrofobowy zwiększa ich zastosowanie i efektywność w emulsjach spożywczych [39]. Coraz większa świadomość wśród konsumentów sprawia, że żywność zawierająca konserwanty pochodzenia naturalnego, staje się atrakcyjniejsza i częściej wybierana od produktów zawierających przeciwutleniacze syntetyczne.

Antyoksydanty fenolowe zapobiegają procesom rozkładu, które zachodzą w przetworzonej i przechowywanej żywności. Opóźniają procesy jełczenia oksydatywnego tłuszczów, przez co są stosowane do konserwacji majonezu, margaryn, masła, sosów, twarogów, jogurtów oraz wyrobów mięsnych. Do wymienionych produktów często stosuje się bogaty w kwas ferulowy- ekstrakt rozmarynowy [57].

Poza właściwościami przeciwutleniającymi związków polifenolowych wykorzystuje się również ich właściwości barwiące. Do stabilizacji i wzmacniania barwy napojów, deserów i wyrobów cukierniczych stosowane są gównie antocyjany. Pochodne kwasu ferulowego – kwas kawowy i chlorogenowy nadają ciemną barwę rodzynkom, suszonym śliwkom i daktylom, na skutek enzymatycznego brunatnienia [58]. Ekstrakty i susze, zawierające polifenole, stanowią również naturalne antyseptyki ograniczając rozwój bakterii.

Kosmetyka. Kwas ferulowy jest dopuszczony do stosowania w kosmetykach zgodnie z Decyzją Komisji WE z dnia 9.02.2006 r. zmieniającą decyzję 96/335/WE, ustanawiającą wykaz i powszechne nazewnictwo składników stosowanych w produktach kosmetycznych. Zawarty jest w preparatach kosmetycznych pod zgodną z INCI nazwą: „Ferulic acid'' i według wykazu pełni w nich funkcje przeciwdrobnoustrojowe. Dodawany do różnych form kosmetycznych przedłuża ich trwałość, zabezpieczając w szczególności przed niekorzystnymi procesami utleniania. Ponad to ma zdolność do stabilizowania innych, powszechnie stosowanych antyoksydantów, takich jak witamina C i E. Obecnie wzrasta również zainteresowanie kwasem ferulowym jako potencjalnym filtrem UV. Wykazano jego właściwości ochronne w stosunku do różnych struktur skóry, w tym keratynoctów, fibroblastów, kolagenu i elastyny. Badania nad ochronnym działaniem FA potwierdziły, że komórki poddawane oddziaływaniu promieniowania UV, są dużo mniej podatne na fotouszkodzenia [59, 60, 61].

Kwas ferulowy wykorzystywany jest zarówno jako składnik preparatów do pielęgnacji domowej (zwykle w stężeniu 0,5-1%), jak i w produktach użytku profesjonalnego - w gabinetach kosmetologicznych i dermatologicznych. Stanowi łagodną alternatywę dla agresywnych substancji chemoeksfoliujących. Stosowany w postaci całorocznych peelingów chemicznych (zwykle w stężeniu 12-20%) jest łagodny dla skóry, nie powoduje widocznego złuszczania naskórka [62, 63].

Właściwości i wpływ kwasu ferulowego na skórę przedstawiono w Tabeli 2 [39, 59, 64-68].

Tab. 2. *Właściwości i wpływ kwasu ferulowego na skórę*

Właściwości	Mechanizm działania
Antyoksydacyjne	• Neutralizuje wolne rodniki zapobiegając uszkodzeniom DNA, fibroblastów i keratynocytów, rozkładowi kolagenu i elastyny, • Zapobiega peroksydacji fosfolipidów błon komórkowych, • Chelatuje jony metali przejściowych, • Wspiera endogenne systemy antyoksydacyjne chroniąc enzymy (glutation, katalazę, dysmutazę ponadtlenkową) przed degradacją i uczestnicząc w ich regeneracji.
Rozjaśniające	• Pełni rolę inhibitora tyrozynazy- głównego enzymu melanogenezy, • Hamuje proliferację melanocytów, • Hamuje transfer melanosomów do keratynocytów.
Przeciwstarzeniowe	• Zmniejsza degradację kolagenu poprzez hamowanie syntezy metaloproteinaz (MMP-2 i MMP-9), • Hamuje elastozę poprzez znaczną redukcję ilości reaktywnych form tlenu, które pobudzają ekspresję mRNA tropoelastyny.
Fotoochronne	• Absorbuje promieniowanie UV w zakresie 290-320 nm
Przeciwzapalne, przeciwalergiczne	• Hamuje aktywność cytokin prozapalnych (IL1 i IL6 oraz TNFα), lipooksygenazy i cyklooksygenazy.
Poprawiające mikrokrążenie	• Indukuje syntezę nowych naczyń krwionośnych poprzez wpływ na czynniki wzrostu (VEGF, PDGF, HIF-1).
Przyspieszające regenerację skóry i gojenie ran	• Przyspiesza epitelializację, • Zwiększa w uszkodzonej tkance zawartość hydroksyproliny i hydroksylizyny- prekursorów kolagenu.

1.4 Mikronakłuwanie skóry

Mezoterapia mikroigłowa (ang. microneedling) jest jedną z metod poprawiających wygląd i funkcje skóry poprzez wywoływanie w niej kontrolowanego stanu zapalnego, prowadzącego do procesów samoodnowy, przebudowy i regeneracji. Zabieg polega na gęstym, intensywnym nakłuwaniu skóry za pomocą specjalnych dermarollerów lub dermapenów i wskazany jest przede wszystkim przy skórze z objawami starzenia, utratą napięcia, zmarszczkami, a także w niwelowaniu blizn i rozstępów. W zależności od wskazań i głębokości nakłuć, zabiegi wykonuje się w seriach (4-8 zabiegów), w 10-14 - dniowych odstępach czasu [69, 70].

Powstające mikrouszkodzenia stanowią dobrą drogę wnikania substancji aktywnych, znajdujących się w preparatach rekomendowanych do mezoterapii mikroigłowej. Zwiększenie przenikania transepidermalnego znacznie podnosi skuteczność zabiegu i poszerza możliwości jego zastosowania [71, 72]. Wykorzystuje się regenerujące mikronakłuwanie z działaniem wybranych substancji np. lipolitycznych lub pobudzających wzrost włosów, tego typu zabiegi łączone stosuje się także przy niwelowaniu defektów skóry takich jak cellulit, bielactwo [73-75].

Mechanizm działania. Nakłuwanie skóry cieniutkimi igłami prowadzi do uszkodzenia powierzchownych, drobnych naczyń krwionośnych powodując mikrokrwawienie. Zapoczątkowuje to proces analogiczny do procesu gojenia się ran, obejmujący 3 główne fazy: zapalenia, proliferacji i przebudowy (remodelingu) [70, 76]. Istotą fazy zapalnej jest formowanie się skrzepów tamujących krwawienie, napływ komórek układu immunologicznego oraz niezwykle istotna, z punktu widzenia przebudowy skóry - aktywacja płytek krwi. Pobudzenie trombocytów prowadzi do uwalniania wielu czynników wzrostu m.in.: płytkowego czynnika wzrostu (ang. platelet-derived growth factor - PDGF), transformującego czynnika wzrostu α i β (ang. transforming growth factor - TGF α i β), czynnika wzrostu fibroblastów 2 (ang. fibroblast growth factor - FGF-2), naskórkowego czynnika wzrostu (ang. epidermal growth factor - EGF). Czynniki wzrostu przyspieszają podziały i różnicowanie się komórek skóry oraz silnie stymulują fibroblasty do produkcji kolagenu i elastyny [70, 77, 78]. Faza zapalna, po około 72 godzinach, płynnie przechodzi w trwającą 2-3 tygodnie fazę proliferacji, w której postępuje epitelializacja

oraz zastępowanie skrzepów fibrynowych, bogatą w naczynia włosowate tkanką ziarninową. Analogicznie z procesem angiogenezy zachodzi neokolageneza, podczas której wytwarzany jest głównie kolagen typu I i III. Procesy migracji i stymulacji fibroblastów są regulowane przez metaloproteinazy, interleukiny i czynniki wzrostu (TGF-β, PDGF, EGF) [79-81]. Podczas ostatniej fazy - remodelingu zachodzi dalsza transformacja macierzy zewnątrzkomórkowej z postępującym zagęszczaniem i poprawą topografii skóry. Badania histopatologiczne skóry, poddanej serii zabiegów mikronakłuwania, wskazują na niemal 4-krotne zwiększenie ilości włókien kolagenowych i elastynowych. Struktura nowo wytworzonych włókien nie odbiega od tych, znajdujących się w skórze nieuszkodzonej. Pogrubieniu ulega także warstwa ziarnista naskórka. Dzięki temu skóra zyskuje większe napięcie, wytrzymałość, odporność na urazy, a także dochodzi do wyrównania kolorytu i wygładzenia jej powierzchni [71, 72, 82].

Główne wskazania do zastosowania. Jednym z podstawowych wskazań do zastosowania serii zabiegów mezoterapii mikrogiłowej jest starzenie się skóry. Mikronakłuwanie stanowi skuteczną metodę niwelowania zmarszczek oraz poprawy napięcia i elastyczności skóry, bez ryzyka wywołania nadmiernego, niekontrolowanego stanu zapalnego, skutkującego często późniejszą nadwrażliwością skóry [83, 84]. Pełny efekt serii zabiegów uzyskiwany jest po około 3 miesiącach od jej zakończenia, co jest związane z długością trwania procesów neokolagenezy [85]. W celu zwiększenia efektów przeciwstarzeniowych zaleca się połączenie mezoterapii z preparatami zawierającymi witaminy A i C [71].

Procesy przebudowy i silnej stymulacji syntezy nowego kolagenu, zachodzące po zabiegach mikronakłuwania, są bardzo pożądane również w przypadku terapii blizn i rozstępów. Uważa się, że główną rolę w przebudowie tkanki bliznowatej odgrywają, pobudzone nakłuwaniem, metaloproteinazy rozkładające nieprawidłowo ułożone włókna kolagenowe. Z kolei silna stymulacja fibroblastów i postępujące wytwarzanie nowego kolagenu o prawidłowym, równoległym przebiegu, prowadzi do znacznego zagęszczenia skóry, spłycając blizny i zmniejszając ich widoczność [86]. Najlepsze efekty uzyskiwane są w przypadku blizn zanikowych np. potrądzikowych [87]. Zabieg uważa się za bezpieczny również u osób z ciemniejszym fototypem

(typ IV i V według skali Fitzpatricka), u których inne dostępne metody terapeutyczne predysponują do powstawania hiperpigmentacji [88].

Mezoterapię mikroigłową stosuje się także w terapiach łączonych, wykorzystując działanie składników aktywnych dostępnych preparatów kosmetycznych, a nawet leków oraz innych technologii zabiegowych takich jak światło (terapia światłem LED, terapia fotodynamiczna PDT). Wykazano, że połączenie działania co najmniej dwóch różnych procedur daje lepsze, synergistyczne efekty, niż zastosowanie każdej z nich samodzielnie [89]. Powszechnie stosowany w leczeniu łysienia androgenowego minoksydyl, daje dużo lepsze efekty terapeutyczne w połączeniu z mikronakłuwaniem. Zaobserwowano znacznie większą ilość nowych mieszków włosowych, w porównaniu do terapii samym lekiem [75]. Poprawę wykazano w przypadku zastosowania 5-fluorouracylu i takrolimusu w leczeniu bielactwa. Poprzedzenie ich aplikacji gęstymi, drobnymi nakłuciami dało większą skuteczność [74]. Także zmiany hiperpigmentacyjne ulegają rozjaśnieniu w większym stopniu, kiedy połączy się dostępne substancje przeciwprzebarwieniowe, takie jak kwas traneksamowy z mezoterapią mikroigłową. Szczególnie dobre efekty osiągane są w przypadku ostudy (melasmy) [90]. Do innych substancji stosowanych w połączeniu z mikronakłuwaniem należą: peelingi chemiczne, retinoidy, komórki macierzyste, osocze bogatopłytkowe [91-95].

2 CZĘŚĆ BADAWCZA

2.1 Założenia i cele pracy

Założenia pracy:

W pracy postanowiono ocenić wpływ kwasu ferulowego w formie peelingu chemicznego na wybrane parametry skóry twarzy. W celu zoptymalizowania możliwych do osiągnięcia efektów postanowiono porównać aplikację samego kwasu ferulowego, z zabiegiem łączonym obejmującym mikronakłuwanie poprzedzone aplikacją peelingu z kwasem ferulowym. Dokonano także porównania skuteczności z inną powszechnie stosowaną, silną substancją antyoksydacyjną - kwasem askorbinowym (witaminą C). W świetle obecnej wiedzy wiadomo, że kwas ferulowy wywiera korzystny wpływ na hodowle komórkowe fibroblastów, keratynocytów, melanocytów, chroniąc je przed niekorzystnym wpływem promieniowania UV, głównie dzięki właściwościom antyoksydacyjnym. Dostępnych jest jednak niewiele danych literaturowych oceniających wpływ kwasu ferulowego na skórę probantów.

Cele pracy:

1) Ocena aparaturowa wpływu kwasu ferulowego na: nawilżenie, poziom melaniny, nasilenie rumienia, topografię, elastyczność skóry.
2) Ocena porównawcza wpływu kwasu ferulowego oraz kwasu ferulowego z mikronakłuwaniem na wybrane parametry skóry: nawilżenie, poziom melaniny, nasilenie rumienia, topografię, elastyczność.
3) Ocena porównawcza wpływu kwasu ferulowego oraz witaminy C na wybrane parametry skóry: nawilżenie, poziom melaniny, nasilenie rumienia, topografię, elastyczność.
4) Ocena skuteczności zastosowanych zabiegów na podstawie dokumentacji fotograficznej.

2.2 Materiał i metody

2.2.1 Charakterystyka grupy badanej

Badaniem objęto 56 osób (płci żeńskiej), w przedziale wiekowym od 39 do 61 lat, o średniej wieku 54,2, które podzielono na 3 grupy (Tab. 3.). Badane osoby zostały zaklasyfikowane jako II i III fototyp skóry według skali Fitzpatricka. Stopień zaawansowania fotostarzenia został określony na postawie skali Glogau. Charakterystykę grup badanych pod względem klasyfikacji fototypu i typu fotostarzenia przedstawiają tabele nr 4, 5 i 6.

Badane osoby nie posiadały przeciwskazań do wykonania zabiegów. Zostały poproszone o rezygnację z innych procedur kosmetycznych i dermatologicznych na czas trwania badania. Probanci zostali poinstruowani w zakresie postępowania i pielęgnacji okołozabiegowej.

Tab. 3. *Charakterystyka grupy badanej*

Grupa	Zabiegi	Liczba osób	Średnia wieku
Grupa I	Peeling kwasem ferulowym (cała twarz)	20	54,35
Grupa II	Peeling kwasem ferulowym (lewa strona twarzy) Peeling kwasem ferulowym i mikronakłuwanie (prawa strona twarzy)	16	53,9
Grupa III	Peeling kwasem ferulowym (lewa strona twarzy) Witamina C (prawa strona twarzy)	20	54,3

Tab. 4. *Charakterystyka grupy I (peeling kwasem ferulowym)*

	Wiek	**Fototyp FC***	**Typ wg skali Glogau****
1	59	III	IV
2	51	II	IV
3	57	II	II
4	58	II	II
5	45	II	II
6	49	III	II
7	60	III	IV
8	55	II	IV
9	56	II	II
10	53	II	II
11	48	II	II
12	60	III	IV
13	58	II	IV
14	52	II	II
15	57	II	II
16	55	II	II
17	54	II	II
18	50	II	II
19	51	II	II
20	59	II	II

* Fototyp FC – Fototyp skóry według Fitzpatricka (Fitzpatrick skin phototype classification):

I- Bardzo jasna skóra, nigdy się nie opala, zawsze ulega oparzeniu, włosy jasny blond, jasne oczy,

II- Jasna skóra, opala się z trudem, rude lub blond włosy, zwykle niebieskie, zielone lub jasnobrązowe oczy,

III- Dość jasna karnacja, skóra ulega stopniowemu opaleniu, rzadko ulega oparzeniu, włosy ciemny blond lub jasny brąz, kolor oczu dowolny,

IV- Jasnobrązowa skóra, łatwo się opala, bardzo rzadko ulega oparzeniu, włosy brązowe, oczy zwykle ciemne,

V- Skóra brązowa, prawie nigdy nie ulega oparzeniu, włosy ciemnobrązowe, oczy ciemne,

VI- Skóra ciemnobrązowa, nigdy nie ulega oparzeniu, włosy ciemnobrązowe lub czarne, oczy ciemne.

****** Typ wg skali Glogau:

I- Wczesne objawy fotostarzenia - pierwsze zmarszczki, drobne, nieliczne przebarwienia,

II- Umiarkowane do średnich objawy fotostarzenia - bardziej widoczne i głębsze zmarszczki, widoczne przebarwienia posłoneczne, nierównomierna tekstura skóry,

III- Średnie do zaawansowanych objawów fotostarzenia - widoczne wyraźne zmarszczki mimiczne i statyczne, skóra poszarzała, o nierównomiernym kolorycie i przebarwieniach, teleangiektazje,

IV- Zaawansowane do ciężkich objawów fotostarzenia - głębokie zmarszczki i bruzdy, liczne plamy soczewicowate, posłoneczne zmiany przerostowe, skóra o żółto-szarym zabarwieniu, często obecne wczesne zmiany nowotworowe.

Tab. 5. *Charakterystyka grupy II (peeling kwasem ferulowym + mikronakłuwanie)*

	Wiek	**Fototyp FC***	**Typ wg skali Glogau****
1	49	II	II
2	58	II	IV
3	54	II	II
4	53	III	IV
5	60	II	II
6	59	III	IV
7	45	II	II
8	59	II	IV
9	53	III	II
10	52	II	II
11	49	II	II
12	55	II	IV
13	57	II	IV
14	53	II	II
15	52	II	II
16	48	II	II

* Fototyp FC – Fototyp skóry według Fitzpatricka (Fitzpatrick skin phototype classification)

****** Typ wg skali Glogau

Tab. 6. *Charakterystyka grupy III (peeling kwasem ferulowym + witamina C)*

	Wiek	**Fototyp FC***	**Typ wg skali Glogau****
1	59	III	IV
2	55	II	IV
3	52	II	II
4	59	II	II
5	41	II	II
6	60	III	II
7	52	III	IV
8	59	II	IV
9	61	II	II
10	39	II	II
11	48	II	II
12	56	III	IV
13	58	II	IV
14	57	II	II
15	49	II	II
16	50	II	II
17	61	II	II
18	56	II	II
19	59	II	II
20	55	II	II

* Fototyp FC – Fototyp skóry według Fitzpatricka (Fitzpatrick skin phototype classification)

**** Typ wg skali Glogau

2.2.2 Procedury zabiegowe

Każdej z probantek wykonano 8 zabiegów, z częstotoliwością 1 raz w tygodniu, z wykorzystaniem peelingu chemicznego na bazie 14% kwasu ferulowego (pH=4,0-5,0) – DNA Recovery Peel firmy Mediderma® (INCI: Ferulic Acid, Propylene Glycol). Preparat został opracowany w technologii nanosomowej, aby zwiększyć penetrację składnika aktywnego. Dodatkowo po demakijażu, a przed aplikacją peelingu spryskiwano twarz preparatem zawierającym puste nanosomy - Sensyses Liposomal Cleanser, przygotowującym skórę do zabiegu. W zależności od grupy badanej aplikowano peeling na całą lub na jedną połowę twarzy. Dokładne procedury opisano poniżej.

Aplikacja peelingu chemicznego na bazie kwasu ferulowego na całą twarz - Grupa I

Zabiegi rozpoczynały się dokładnym demakijażem skóry delikatnym preparatem Cleansing Milk firmy Mediderma®, a następnie dezynfekcją z użyciem preparatu Skinsept®Pur na bazie alkoholu etylowego. Oczyszczoną skórę spryskiwano preparatem Sensyses Liposomal Cleanser, a następnie aplikowano 2 warstwy peelingu DNA Recovery Peel Solution w kilkuminutowych odstępach czasu (łącznie 1,5 ml preparatu). Każda z warstw była dokładnie wmasowana w skórę (zgodnie z zaleceniami producenta). Zalecono samodzielne zmycie peelingu przez probantów po 6-8 godzinach od aplikacji, z użyciem płatków kosmetycznych i letniej wody, a następnie aplikację kremów przeciwsłonecznych z wysokim filtrem (w porze dziennej).

Aplikacja peelingu z kwasem ferulowym na lewą połowę twarzy oraz peelingu z kwasem ferulowym w połączeniu z mikronakłuwaniem na prawą połowę twarzy – Grupa II (zabieg typu split-face)

W pierwszym etapie aplikowano peeling chemiczny na bazie kwasu ferulowego na całą twarz, zgodnie z procedurą opisaną powyżej (dla Grupy I). Następnie na prawej połowie twarzy wykonywane było mikronakłuwanie z użyciem Derma N-Skin Pen firmy Symbiosis®. Używano jednorazowych sterylnych kartridży, zawierających 12 igieł ze stali nierdzewnej. Wysuw igieł dostosowywany był do okolicy - tak, aby nie powodować krwawienia- 0,25 mm w okolicy czoła i 0,5 mm na pozostałej części twarzy. Do nakłuwania skóry wykorzystano „metodę kratkową'' wykonując ruchy w kierunkach pionowych, poziomych i ukośnych, z prędkością 1300 uderzeń/minutę. Za punkt końcowy zabiegu obrano pojawienie się delikatnego zaczerwienienia skóry. Następnie tak jak w przypadku Grupy I - probanci zostali poproszeni o przemycie skóry letnią wodą po 6-8h od zabiegu oraz aplikację kremów przeciwsłonecznych z wysokim filtrem (w porze dziennej).

Aplikacja peelingu z kwasem ferulowym na lewą połowę twarzy oraz serum z kwasem askorbinowym na prawą połowę twarzy - Grupa III (zabieg typu split-face)

Na lewej połowie twarzy wykonywano zabieg zgodnie z procedurą opisaną dla grupy I. Na prawej połowie twarzy również wykonywano etapy demakijażu, dezynfekcji i przygotowania skóry preparatem z pustymi nanosomami, zgodnie z wcześniejszym postępowaniem, z użyciem tych samych preparatów. Następnie na oczyszczoną skórę (wyłącznie prawej strony twarzy) aplikowano 2 warstwy serum zawierającego kwas askorbinowy o stężeniu 12% - C-Vit Intensive Serum firmy Sesderma® (INCI: Ascorbic Acid, Propylene Glycol), w ilości 1,5 ml. Każda z warstw była wmasowywana w skórę w kilkuminutowych odstępach czasu (analogicznie do aplikacji peelingu ferulowego). Wykorzystywany preparat został stworzony również w oparciu o technologię nanosomową. Tak jak w przypadku Grupy I i II preparaty były zmywane letnią wodą, samodzielnie przez probantki po 6-8h od ich aplikacji. W porze dziennej stosowane były kremy przeciwsłoneczne z wysokim filtrem.

Każda z probantek wyraziła dobrowolną, świadomą, pisemną zgodę na udział w procedurze badawczej. Projekt badawczy i wszystkie stosowane w jego obrębie procedury zostały pozytywnie zaopiniowane i zatwierdzone przez Komisję Bioetyczną Uniwersytetu Medycznego w Łodzi nr o. RNN/81/19/KE z dnia 12.02.2019 r. (Załącznik 8.2)

2.2.3 Ocena aparaturowa

Przed przystąpieniem do serii zabiegów, bezpośrednio po zakończeniu serii oraz po miesiącu od ostatniego zabiegu, zostały wykonane pomiary wybranych parametrów skóry, sondami: Mexameter, Korneometer, Cutometer urządzenia MPA - The Multi Probe Adapter Systems (Courage + Khazaka electronic GmbH, Köln, Germany) oraz kamerą Visioscan® VC 98. Wszystkie pomiary wykonywane były w tym samym pomieszczeniu, z zachowaniem stałych warunków temperatury (24-26◦C) i wilgotności powietrza (33-41%), zawsze o zbliżonej porze dnia (14-16 godzina). Przed pomiarami probanci byli proszeni o 10-15 minutową aklimatyzację w pomieszczeniu pomiarowym.

Wyznaczono 4 punkty pomiarowe (Ryc. 4.):

1- na czole (na przecięciu linii pionowej przechodzącej przez zewnętrzny kąt oka i linii poziomej w odległości 2 cm od brwi),
2- na policzku (na przecięciu linii pionowej przechodzącej przez zewnętrzny kąt oka i linii poziomej wyznaczającej koniec skrzydełka nosa),
3- w okolicy żuchwy (na przecięciu linii pionowej przechodzącej przez zewnętrzny kąt oka i linii poziomej przechodzącej przez kącik ust),
4- punkt kontrolny (nie poddawany zabiegom) - fragment skóry za prawym uchem.

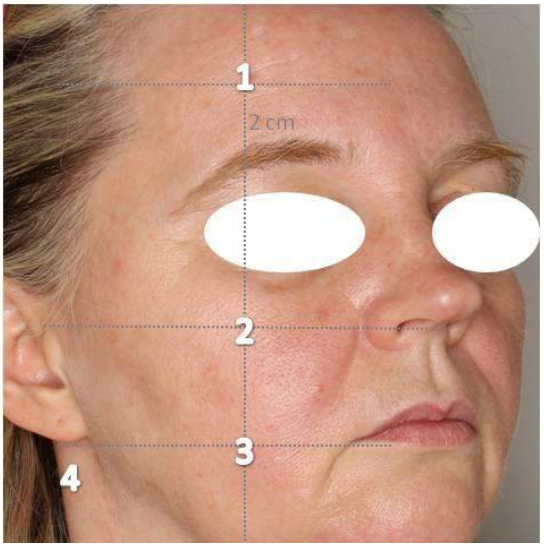

Ryc. 4. *Punkty pomiarowe*

Każdy z pomiarów, w każdym miejscu, wykonywano 3-krotnie, a następnie zapisywano wynik jako średnią z pomiarów.

2.2.3.1 Ocena zabarwienia skóry i nasilenia rumienia - sonda meksametryczna

Meksameter® MX 18 jest urządzeniem służącym do pomiaru zabarwienia skóry. Zasada działania opiera się na emisji, a następnie absorpcji i odbiciu światła o określonej długości fali (światło zielone 568nm, czerwone 660nm, podczerwone 880nm). Sonda wbudowana w aparat wysyła wiązkę światła, która zostaje w określonym stopniu zaabsorbowana przez barwniki skóry- melaninę i hemoglobinę. Niepochłonięta przez chromofory ilość światła, zostaje odbita i trafia z powrotem do odbiornika sondy pomiarowej. Pomiar trwa 1s, a jego wynik przedstawiany jest w jednostkach arbitralnych (0-999 dla melaniny i hemoglobiny). Przy ciemniejszej skórze występuje większa absorpcja promieniowania i większe nasilenie rumienia (Ryc. 5.) [96].

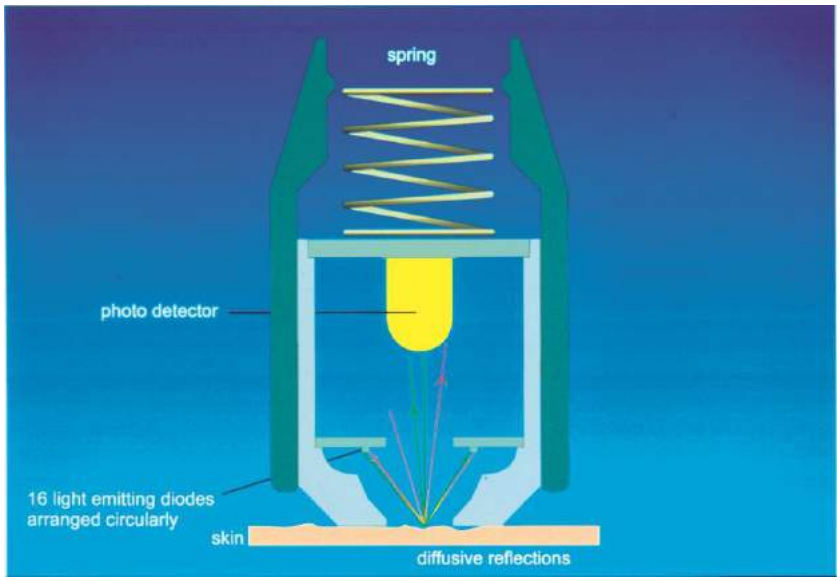

Ryc. 5. *Zasada pomiaru dokonywanego przez Meksametr*

Źródło: https://courage-khazaka.de/en/scientific-products/all-products

2.2.3.2 Ocena nawilżenia skóry - sonda korneometryczna

Corneometer® CM 825 służy do oceny nawilżenia, poprzez pomiar zawartości wody w warstwie rogowej naskórka. Urządzenie oparte jest na pomiarze pojemności elektrycznej, tzw. dielektrycznego (nieprzewodzącego prądu) medium. Sonda zbudowana jest z kwadratowej płytki, na której umieszczone są elektrody, stanowiące okładki kondensatora. Mierzona skóra stanowi warstwę dielektryczną. Zasięg pomiaru to ok. 10-20 µm, przy wykorzystywanym prądzie o częstotliwości 09-1,2 MHz. Wyniki, podobnie jak w przypadku Mexametru wyświetlane są w jednostkach arbitralnych (0-120) (Ryc. 6.) [97, 98].



Ryc. 6. *Zasada pomiaru dokonywanego przez Korneometr*

Źródło: https://courage-khazaka.de/en/scientific-products/all-products

2.2.3.3 Ocena elastyczności skóry - sonda kutometryczna

Cutometer® Dual MPA 580 służy do oceny elastyczności skóry. Zasada działania (Ryc. 7.) opiera się na pomiarze mechanicznego odkształcenia skóry- fragment o średnicy 2 mm zostaje zassany do otworu sondy dzięki wytworzeniu podciśnienia, a następnie po zaprzestaniu jego działania, skóra wraca do pierwotnego kształtu, wycofując się z otworu. Dzięki systemowi optycznych soczewek urządzenie dokonuje pomiaru głębokości zassania skóry do jego wnętrza. Podczas pomiarów wykorzystywano tryb pomiarowy o wartości podciśnienia 450 mbar [99, 100].

Ocenie poddano 2 spośród kilkunastu parametrów:

R2 - tzw. lepko-sprężystość (ang. visco-elasticity) - stosunek całkowitej elastyczności skóry do całkowitego rozciągnięcia (Ua/Uf). Im wyższa jego wartość, tym większa elastyczność skóry.

R7 - stosunek natychmiastowego powrotu po odkształceniu do całkowitego rozciągnięcia (Ur/Uf). Im wyższa jego wartość, tym większa elastyczność skóry (Ryc. 8.).

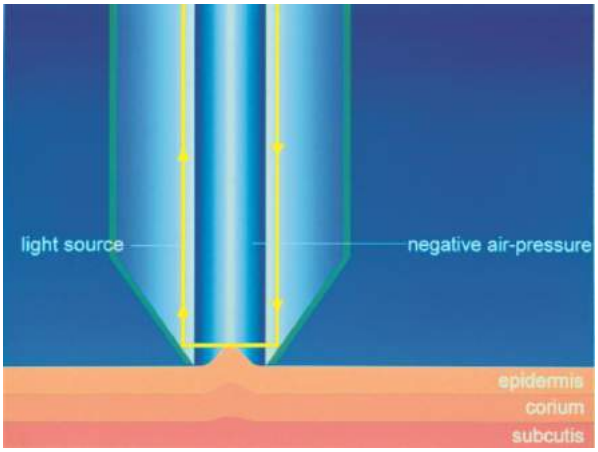

Ryc. 7. *Zasada pomiaru dokonywanego przez Kutometr*

Źródło: https://courage-khazaka.de/en/scientific-products/all-products

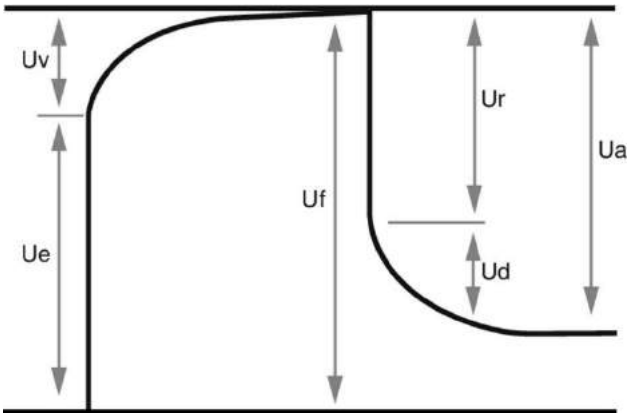

Ryc. 8. *Krzywa deformacji skóry uzyskana za pomocą Kutometru [100]*

2.2.3.4 Ocena topografii skóry- kamera Visioscan

Visioscan® VC 98 jest kamerą UVA o wysokiej rozdzielczości, pozwalającą na dokładne zbadanie topografii skóry. Czujniki wbudowane w sondę, odbierają zmarszczki i załamania skóry jako pixele ciemne, a łuszczący się naskórek jako pixele jasne. Specjalne oprogramowanie, na podstawie proporcji różnej intensywności pixeli, wylicza parametry takie jak m.in. złuszczanie (SEsc) i szorstkość (SEr) naskórka. SEsc (scaliness) jest wyrażoną w jednostkach arbitralnych wartością, obrazującą poziom złuszczania warstwy rogowej naskórka, z uwzględnieniem wartości nawilżenia. W obrazie kamery widoczny jest jako zagęszczenie szarych pixeli. SEr jest parametrem chropowatości skóry, na obrazie widocznym jako pixele ciemne. Obie wartości rosną wraz z wiekiem [101, 102].

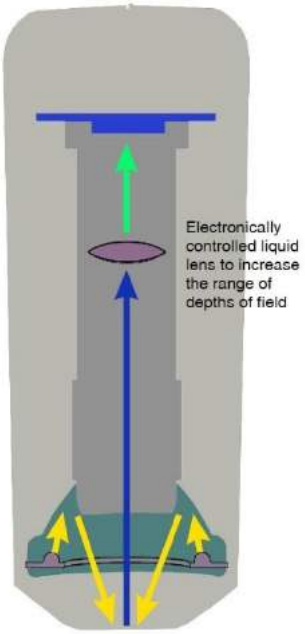

Ryc. 9. *Zasada pomiaru dokonywanego przez Visioscan*

Źródło: https://courage-khazaka.de/en/scientific-products/all-products

2.2.4 Dokumentacja fotograficzna

Przed przystąpieniem do badania oraz po zakończeniu serii zabiegów, wykonano zdjęcia systemem fotograficznym VISIA® Complexion Analysis System (Canfield Scientific, Inc.) oraz Fotomedicus (Elfo®). Oba urządzenia stanowią zintegrowany system fotograficzny ze specjalnym oprogramowaniem, umożliwiającym dokumentację przebiegu terapii zabiegowych poprzez analizę stanu skóry z uwzględnieniem cech takich jak: głębokość zmarszczek, obecność przebarwień, widoczność teleangiektazji.

Zdjęcia były wykonywane w pięciu ustawieniach: na wprost, profil prawy, profil lewy (Ryc. 10.) oraz lewe środkowo -boczne ustawienie i prawe środkowo-boczne ustawienie (Ryc. 11.).

Ryc. 10. *Dokumentacja fotograficzna- ustawienie na wprost, profil lewy, profil prawy*

Ryc. 11. *Dokumentacja fotograficzna- ustawienie lewe środkowo-boczne i prawe środkowo-boczne*

Dodatkowo system VISIA posiada technologię RBX (Red/Brown Subsurface Analysis) zapewniającą możliwość analizy stanu podpowierzchniowych naczyń krwionośnych (Ryc. 12.).

Ryc. 12. *Dokumentacja fotograficzna - sieć powierzchownych naczyń krwionośnych*

2.3 Wyniki

Szczegółowa analiza, interpretacja oraz dyskusja uzyskanych wyników badań została ujęta w formie trzech publikacji w czasopismach z listy JCR, załączonych poniżej.

Spis publikacji będących przedmiotem rozprawy doktorskiej:

1. **Zduńska K**, Rotsztejn H. The effectiveness of ferulic acid and microneedling in reducing signs of photoaging: A split-face comparative study. Dermatol Ther. 2020 Nov;33(6):e14000. doi: 10.1111/dth.14000.
   70 pkt. IF: 2,851

2. **Zduńska-Pęciak K**, Kołodziejczak A, Rotsztejn H. Two superior antioxidants: Ferulic acid and ascorbic acid in reducing signs of photoaging - A split-face comparative study. Dermatol Ther. 2022 Feb;35(2):e15254. doi: 10.1111/dth.15254.
   70 pkt. IF: 2,851

3. **Zduńska-Pęciak K**, Debowska R, Kołodziejczak A, Rotsztejn H. Ferulic acid - a novel topical agent in reducing signs of photoaging. Dermatol Ther. 2022 Apr;29:e15543. doi:10.1111/dth.15543
   70 pkt. IF: 2,851

Wartość dodaną do niniejszej pracy stanowią ściśle powiązane z tematem rozprawy, dwa artykuły poglądowe, opublikowane w czasopismach z listy JCR dołączone do sekcji „Załączniki''.

1. **Zduńska K**, Kołodziejczak A, Rotsztejn H. Is skin microneedling a good alternative method of various skin defects removal. Dermatologic Therapy 2018 Nov;31(6);e12714. https://doi.org/10.1111/dth.12714.
   70 pkt. IF: 1,74

2. **Zduńska K**, Dana A, Kolodziejczak A, Rotsztejn H. Antioxidant Properties of Ferulic Acid and Its Possible Application. Skin Pharmacology and Physiology 2018;31:332–336. doi: 10.1159/000491755. Epub 2018 Sep 20.
   100 pkt. IF: 1,89

Received: 14 May 2020 | Revised: 5 July 2020 | Accepted: 8 July 2020
DOI: 10.1111/dth.14000

ORIGINAL ARTICLE

DERMATOLOGIC THERAPY WILEY

The effectiveness of ferulic acid and microneedling in reducing signs of photoaging: A split-face comparative study

Master Zduńska-Pęciak Kamila | Rotsztejn Helena

Chair of Cosmetology, Department of Cosmetology and Aesthetic Dermatology, Faculty of Pharmacy, Medical University of Łódź, Łódź, Poland

Correspondence
Master Zduńska-Pęciak Kamila, Chair of Cosmetology, Department of Cosmetology and Aesthetic Dermatology, Faculty of Pharmacy, Medical University of Łódź, Muszyńskiego 1 Street, PL-91-151 Łódź, Poland.
Email: kamila.zdunska@stud.umed.lodz.pl

Funding information
Uniwersytet Medyczny w Lodzi, Grant/Award Numbers: 502-03/3-066-01/502-34-102, 503/3-066-01/503-31-001

Abstract

Photoaging is closely related to ultraviolet-induced oxidative stress. Ferulic acid is a plant-based antioxidant with antiaging activity. Combining ferulic acid peel with microneedling enhances its transdermal penetration. This study was designed to evaluate the efficacy of 14% ferulic acid peel combined with microneedling for facial photoaging. Sixteen women aged 45 to 60 years with Fitzpatrick skin types II and III were enrolled in this trial. All patients received eight treatment sessions with a full face application of chemical peeling based on 14% ferulic acid in 1-week intervals. During each session, on the right half of patient's face, peeling application was followed by microneedling. Efficacy was measured using Multi Probe Adapter (Courage + Khazaka electronic). The measurement of hydration, elasticity, melanin index, and erythema index were taken before treatments, after eighth session and 1 month after the last application. The objective evaluation showed statistically significant improvement in all measured skin parameters ($P < .05$), after ferulic acid peel application, as well as ferulic acid peel followed by microneedling. Combined therapy showed significantly greater improvement especially in skin elasticity, comparing to peeling administered alone. Ferulic acid has a significant bleaching, antiredness, smoothing, and moisturizing activity. When combined with microneedling, the efficiency is increased, in particular regarding skin elasticity.

KEYWORDS
antioxidant, ferulic acid, microneedling, photoaging

1 | INTRODUCTION

Solar ultraviolet (UV) radiation is one of the most common external factor contributing to skin aging.[1] As photoaging is widely occurring and progressive process, it is essential to develop the innovative treatment options.

Ferulic acid is a phenolic acid found in various plants, which has been widely used in pharmaceutics and food so far.[2] It has proven anti-inflammatory activity,[3] free radical scavenging activity,[4] antioxidant protection ability,[5] and UV-absorbing ability.[6] This reported effects can indicate that ferulic acid with its high antioxidative and anti-inflammatory activity could prevent and reduce photo-oxidative skin damage, including loss of elasticity, wrinkles, skin dryness, and hyperpigmentations.[7,8] Many histopathological examinations on fibroblasts, keratinocytes, melanocytes have already been done.[9-12] The results of these research show that ferulic acid acts as a protective agent against UV-induced changes in the main skin cells. However, to the best of our knowledge, the benefits of a ferulic acid for photoaging skin on human have not been studied yet.

It is considered that transfer of active substances through the epidermal barrier may be limited.[13] What is more, the usage of ferulic acid in cosmetic formulations may be limited by its tendency to be rapidly oxidized.[14,15] To increase the absorption of ferulic acid peel, it was followed by microneedling. During microneedle mesotherapy skin is punctured with very thin needles, which enhances penetration of active ingredients.[13] To compare the effectiveness of ferulic acid peel

 © 2020 Wiley Periodicals LLC.

(alone) with combined treatment including ferulic acid peel and microneedling, in reducing signs of photoaging, we did split-face study.

2 | MATERIALS AND METHODS

2.1 | Participants

This study included 16 patients aged 45 to 60 years, with Fitzpatrick skin types II and III. After clinical evaluation they were classified as moderate (10 patients) to severe (6 patients) facial photoaging, according to Glogau Wrinkle Scale. The participants were informed about possible side effects such as skin irritation, reddening, pruritus, and instructed about behavior during the examination. They were asked to use sunscreen with Sun Protection Factor (SPF) 50, twice a day, during, and 1 month after procedure. They were required to resign from any cosmetic formulations with antiaging active ingredients and dermatological procedures for the entire duration of the study. All patients pledged to comply with the recommendations.

Written informed consent was obtained from each patient before enrollment.

2.2 | Procedures

All patients received a series of eight treatments, performed once a week. After cleaning the skin with the make-up cleansing milk and degreasing it with spray containing ethyl alcohol, two thin layers of peeling, based on 14% ferulic acid, were applied symmetrically across the entire face. Each layer was massaged into the skin until absorbed, according to the producer's recommendations. Then, the right half of the face was microneedled with Dermapen (Derma N-Skin Pen Symbiosis), without causing bleeding. Depend on area, 0.25 mm (forehead) or 0.5 mm (cheek, chin) needle length was used. Disposable cartridges used, included 12 needles of surgical steel. The skin was punctured in horizontal, vertical, and oblique directions with 1300 ejections/minute speed. The end point of microneedling was slight skin reddening. Faces were washed 6 hours after the treatment, using a cotton pad soaked in lukewarm water. Then, subjects dried their faces with clean towel and applied broad-spectrum SPF 50+ sunscreen.

The research project was approved by the Bioethics Committee of the Medical University of Lodz (Protocol No. RNN/81/19/KE).

2.3 | Outcome assessment

Efficacy was measured using The Multi Probe Adapter Systems (Courage + Khazaka electronic GmbH, Köln, Germany). All measurements were taken in the same room, with constant temperature (20°C ± 2°C) and humidity (45% ± 5%) conditions. The first measurement was performed before starting the examination, the second one—immediately after the end of the series (8 weeks after the first treatment) and the third one—1 month after the last treatment (12 weeks after the first treatment). Before measurement, all patients were acclimatized in the measuring room, for at least 15 minutes. Three measurement points were designated: 1—on the forehead, 2—on the cheek, and 3—on the chin. All measurements were done three times in each place. The recorded result is the average of all measurements.

Melanin and Erythema Index (*Mexameter MX 18*): Measurement of the skin color, by the emission, subsequent absorption and reflection of light of a specific wavelength, absorbed by skin chromophores—melanin and hemoglobin. The result is received in arbitrary units (0-999 for melanin and hemoglobin).[16]

Hydration (*CorneometerCM820*): Measurement of the water content in the stratum corneum, based on electrical capacity with measuring range around 10 to 20 μm and electric frequency 09 to 1.2 MHz. The result is received in arbitrary units.[17]

Elasticity (*Cutometer SEM 474*): Measurement of the biomechanical skin properties using negative pressure. Used measurement mode 1: negative pressure: 450 mbar, on-time: 3 seconds, off-time: 3 seconds, repetitions: 3. Evaluated parameters: R2 (Ua/Uf), gross-elasticity of the skin, including viscous deformation and R7 (Ur/Uf), biological elasticity, that is, the ratio of immediate retraction to total distension (Figure 1).[18]

Additionally, before starting the treatment and after its completion photographs were taken with photographic systems VISIAComplexion Analysis System (Canfield Scientific, Inc.) and Fotomedicus (Elfo).

All side effects, occurring right after the treatment, were documented.

2.4 | Statistical analysis

The mean and SD (mean ± SD) was applied as appropriate for description of parameters with normal distribution. Variables that were not normally distributed were expressed as median and interquartile range (IQR: 25%; 75%). The assumption of normality was assessed by the use of Shapiro-Wilk test. One-way repeated measures Analysis of variance (with a Greenhouse-Geisser sphericity correction when appropriate) followed by Bonferroni post hoc tests was performed for

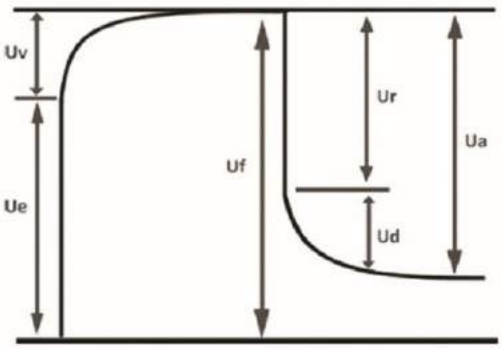

FIGURE 1 Skin deformation curve obtained with a Cutometer[18]

statistical evaluation of differences in skin parameters over time. Differences in percentage changes of skin parameters compared to baseline values between ferulic acid and ferulic acid + microneedling-treated skin were compared according to the Mann-Whitney test. Statistical evaluation of categorical variables was performed by chi-square tests. A *P* value <.05 was considered as statistically significant.

3 | RESULTS

The results of the study demonstrated that when compared to the baseline, both ferulic acid (FA) and ferulic acid with microneedling (FA + microneedling), can result in statistically significant improvements in all measured skin parameters (Tables 1-3).

The biggest difference between both therapies, was observed in case of elasticity. R2 and R7 parameters increased more significantly on the side treated with ferulic acid followed by microneedling. The difference was statistically significant, at the measurements taken right after the series of treatments, as well as a month after the end of the series (Figure 2A,B).

As can be seen in Table 1, the skin hydration level increased significantly for both ferulic acid and ferulic acid with microneedling treatments. Right after the series of treatments, percentage assessment showed there was slightly greater improvement of

TABLE 1 Skin moisture content according to place and time of measurement

Treatment	Measurement place	Period of study			P value
		Base (*)	After 8 weeks (#)	After 12 weeks	
Ferulic acid (left)	I (Forehead)	55.6 ± 10.6	71.0 ± 7.2*** 26.3 (19.7; 37.9)	67.4 ± 9.0*** 10.0 (7.5; 41.4)	P < .0001
	II (Cheek)	47.5 ± 12.8	62.2 ± 13.4*** 27.2 (16.8; 38.6)	59.4 ± 10.8*** 16.4 (7.8; 41.6)	P < .0001
	III (Chin)	34.8 ± 19.0	50.7 ± 17.1*** 64.0 (26.2; 106.2)	50.5 ± 15.9*** 60.0 (13.6; 93.5)	P < .0001
Ferulic acid + microneedling (right)	I (Forehead)	54.5 ± 9.9	72.5 ± 7.1*** 30.6 (26.8; 41.2)	###66.8 ± 7.4*** 19.0 (12.8; 37.9)	P < .0001
	II (Cheek)	48.0 ± 12.2	64.4 ± 12.7*** 28.7 (21.2; 43.0)	##59.3 ± 10.4** 15.9 (8.7; 36.3)	P < .0001
	III (Chin)	35.3 ± 19.0	52.2 ± 17.3*** 66.8 (34.1; 89.5)	###42.3 ± 15.9** 25.7 (1.5; 56.3)$	P < .0001

Note: Data presented as mean ± SD or median with IQR (25%; 75%). Percentage value reflects the changes of parameter from baseline.
*P < .05; **P < .01; ***P < .001 vs base.
#P < .05; ##P < .01; ###P < .001 vs 8 weeks.
$P < 0.05; $$P < 0.01; $$$P < 0.001 vs ferulic acid.

TABLE 2 Melanin value according to place and time of measurement

Treatment	Measurement place	Period of study			P value
		Base (*)	After 8 weeks (#)	After 12 weeks	
Ferulic acid (left)	I (Forehead)	148.1 ± 33.8	128.4 ± 31.9*** −13.2 (−17.1; −8.7)	##135.1 ± 32.6*** −8.5 (−12.4; −4.4)	P < .0001
	II (Cheek)	119.6 ± 32.3	104.1 ± 32.0** −12.9 (−23.7; −5.3)	#118.7 ± 34.7 −0.2 (−10.6; 6.1)	P = .006
	III (Chin)	132.7 ± 26.1	112.8 ± 23.3*** −16.1 (−21.6; −9.3)	118.1 ± 23.3*** −14.6 (−16.2; −3.4)	P < .0001
Ferulic acid + microneedling (right)	I (Forehead)	149.1 ± 32.3	120.5 ± 30.9*** −18.8 (−21.6; −14.9)$$	##132.0 ± 34.3*** −13.0 (−14.0; −8.1)	P < .0001
	II (Cheek)	120.7 ± 33.2	94.2 ± 27.1*** −21.8 (−27.2; −15.5)$	###108.1 ± 30.7*** −10.3 (−12.9; −6.5)$	P < .0001
	III (Chin)	133.4 ± 26.5	108.1 ± 25.6*** −19.4 (−23.3; −16.5)	###114.9 ± 25.4*** −13.0 (−18.8; −10.8)	P < .0001

Data presented as mean ± SD or median with IQR (25%; 75%). Percentage value reflects the changes of parameter from baseline.
*P < .05; **P < .01; ***P < .001 vs base.
#P < .05; ##P < .01; ###P < .001 vs 8 weeks.
$P < 0.05; $$P < 0.01; $$$P < 0.001 vs ferulic acid.

TABLE 3 Erythema value according to place and time of measurement

Treatment	Measurement place	Period of study			P value
		Base (*)	After 8 weeks (#)	After 12 weeks	
Ferulic acid (left)	I (Forehead)	353.7 ± 57.6	307.5 ± 59.8*** −7.5 (−18.5; −5.5)	297.7 ± 55.8*** −15.8 (−22.4; −7.2)	P < .0001
	II (Cheek)	349.2 ± 74.3	308.1 ± 68.8* −5.6 (−20.3; −4.0)	#294.6 ± 69.2** −13.4 (−25.8; −5.3)	P = .001
	III (Chin)	289.6 ± 71.1	260.7 ± 69.3* −8.4 (−14.9; −2.9)	255.9 ± 70.9** −9.4 (−15.8; −4.4)	P = .001
Ferulic acid + microneedling (right)	I (Forehead)	354.2 ± 55.0	303.3 ± 53.5*** −12.6 (−19.8; −9.5)	##326.6 ± 59.1*** −6.7 (−10.3; −4.5)$	P < .0001
	II (Cheek)	347.7 ± 71.7	304.2 ± 64.7*** −9.3 (−17.0; −7.4)	320.3 ± 66.6** −4.6 (−14.3; −2.9)	P < .0001
	III (Chin)	291.6 ± 70.2	252.7 ± 69.1*** −11.3 (−19.9; −9.8)	270.8 ± 72.3*** −5.7 (−11.1; −3.3)	P < .0001

Data presented as mean ± SD or median with IQR (25%; 75%). Percentage value reflects the changes of parameter from baseline.
*P < .05; **P < .01; ***P < .001 vs base.
#P < .05; ##P < .01; ###P < .001 vs 8 weeks.
$P < 0.05; $$P < 0.01; $$$P < 0.001 vs ferulic acid.

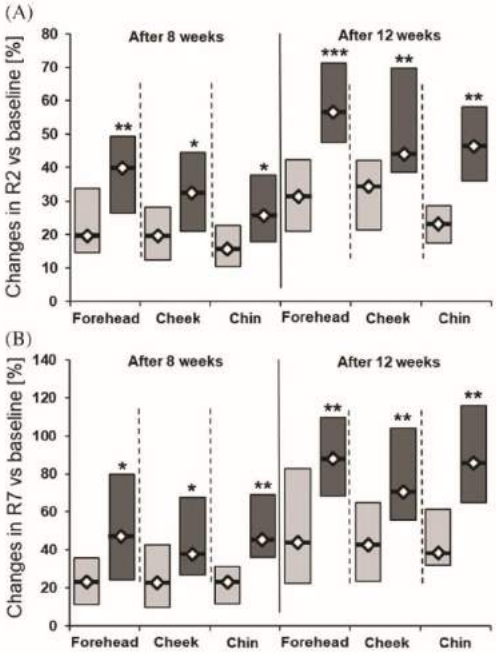

FIGURE 2 A,B, Figure demonstrates R2 alterations (expressed as percentage changes from baseline value) in all measurement and time points. Data presented as median (horizontal bar with a diamond sign) and lowerupper quartile range (box) for skin treated with either ferulic acid peel-left side (light gray box) or ferulic acid peel followed by microneedling-right side (dark gray box). * P < 0.05, ** P < 0.01, ***P < 0.001 vs ferulic acid side

skin moisture content on the FA + microneedling side. A month after the end of the series, on both sides of the face, hydration decreased slightly, still showing a statistically significant difference to the baseline.

Right after a series of treatments, the skin melanin content decreased more on the FA + microneedling side, comparing to the ferulic acid side (statistical significant difference between therapies in two measurement points: I—P < .01; II—P < .05). A month after the end of the series, that parameter increased slightly on the FA + microneedling side, still showing statistical significance in all measurement points, comparing to the baseline values. On the FA side, skin melanin level increased almost to the baseline in one measurement point (II), while the improvement in I and III measurement point where slightly less, but still, significant (Table 2).

The intensity of erythema decreased significantly on both sides of the face, right after the series, as well as a month after the end of the series. On the FA side, the changes in parameter values were slightly less significant, in two measurement points (P = .001), comparing to the significance level on the FA + microneedling side (P < .0001) (Table 3).

The most frequent side effects, observed right after the treatments were erythema, burning sensation and scaling. Incidences of adverse events were significantly higher on the side of the face treated with ferulic acid and microneedling (Table 4). The same percent of patients reported pruritus on both sides of the face (18.7%). Any case of adverse events were not persistent and subsided with couple hours after the treatments.

The results achieved by means of using apparatus are reflected in the photographs by the VISIA Complexion Analysis System (Canfield Scientific, Inc.) and Fotomedicus system (Elfo), taken before and immediately after a series of treatments (Figures 3 and 4).

TABLE 4 Frequent adverse events

Adverse events	Ferulic acid (n%)	Ferulic acid + microneedling (n%)	P value
Pruritus	3 (18.7)	3 (18.7)	P > .999
Erythema	1 (6.2)	12 (75.0)	P < .0001
Burning sensation	2 (12.5)	11 (68.7)	P = .001
Scaling	2 (12.5)	12 (75.0)	P < .001 (.00037)

FIGURE 3 Firming activity of ferulic acid before and after the treatment

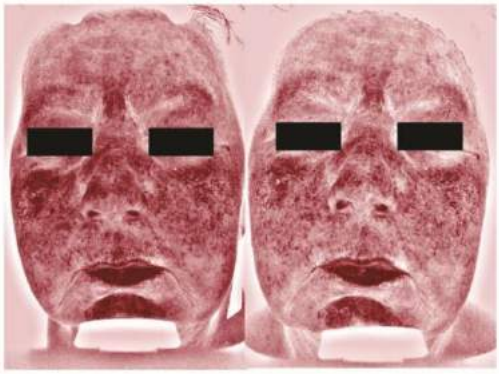

FIGURE 4 Antiredness activity of ferulic acid before and after the treatment

4 | DISCUSSION

Photoaging is a complex, biological process, attributed to continuous, longterm exposure to UV radiation. Among the major clinical changes of skin photoaging there are: dryness, wrinkles, hyperpigmentation, erythema, laxity. Histologically, dermal elastosis, collagen degradation, inflammatory infiltrates can be observed.[19,20] UV-induced oxidative stress is considered to play important role in pathogenesis of photoaging, by causing oxidative damage to cellular components in the skin (via i.a.: oxidation of nucleid acids, proteins, and lipids), activation of proinflammatory cytokines, increase of matrix metalloproteinases (MMPs) expression ([21]).

Ferulic acid as a superior antioxidant[15] has made considerable interest as effective agent for reducing signs of photoaging. The antioxidant mechanism of ferulic acid is based on free radical scavenging, by forming stable phenoxyl radicals, in the reaction of the radical molecule with the antioxidant molecule. In the aftermath, a complex reaction cascade of free radical generation is inhibited. It can also act as a hydrogen donor, giving atoms directly to the radicals.[22-24] The other antioxidant properties of ferulic acid are related to binding transition metals, preventing lipid peroxidation, inhibiting the enzymes that catalyze free radical generation.[25] It also possesses anti-inflammatory properties, associated with reducing proinflammatory cytokines (IL-6, IL-1 β) and tumor necrosis factor-α.[26]

This study demonstrated the efficacy of 14% ferulic acid peel combined with microneedling as a treatment for facial skin photodamage. We did split-face study to compare the effectiveness of ferulic acid peel vs combined therapy comprising peeling followed by microneedle mesotherapy. It is considered, that combining two different procedures, gives their additive and synergistic effects.[27] Microneedling therapy is a popular treatment, used in removing various skin defects (i.a.: photoaging, wrinkles, pigmentation changes, teleangiectasia) through the controlled skin damage. It results in stimulating natural self-repair mechanisms and increasing synthesis of substances that are important building blocks (eg, collagen, elastin, hyaluronic acid, etc.). Breaking skin continuity with thin needles, facilitates the penetration of active ingredients, enhancing its effectiveness.[13]

The results of our study show statistically significant improvement of both ferulic acid peel and ferulic acid peel followed by microneedling, in reducing signs of photoaging. The instrumental analysis of skin parameters, indicate that these treatments significantly affect skin moisture, elasticity, melanin level, and erythema intensity. Importantly, the effects achieved during a series of treatments persist over time. Markiewicz et al also conducted the objective assessment of the efficacy of strong antioxidant L-ascorbic acid in combination with microneedling. Results of their study show significant improvement of skin elasticity and hydration, reduction of skin redness and skin lightening, just after four treatments.[28] El-Domyati et al combined microneedling with other minimally invasive procedures for reducing signs of photoaging. In their split-face study, after six treatment sessions with the use of microneedle mesotherapy and 15% trichloroacetic

acid or platelet rich plasma, they noted significant clinical improvement in wrinkles depth, skin texture, pigmentation intensity. Histological and histometrical analysis showed significant increase in the mean thickness of epidermis, deposition of collagen bundles and formation of new, well-organized elastic fibers.[29]

In our study, we noted the biggest difference between treatments regarding skin elasticity. Comparing both sides of the face, the outcome was more promising with ferulic acid followed by microneedling.

Hye-Jin et al in their study on human dermal fibroblast CCD-986sk, showed the mechanism of anti-aging activity of ferulic acid. It was found, that ferulic acid acts as an inhibitor for MMPs—enzymes accelerating extracellular matrix decomposition, i.a. collagen and hyaluronic acid. What is more, it increases the production of tissue inhibitor of metalloproteinases (TIMP-1[30]). Similar results were obtained by Pluemsamran et al., in their study on human keratinocyte (HaCaT) cells. They proved that ferulic acid inhibits UVA-induced MMP-1 activity[11] These results show that ferulic acid affects the synthesis and decomposition of major skin components, by controlling the activity of enzymes such as MMP-1 and TIMP-1.

The mechanism of antiaging acitivity of microneedling was clinically evaluated in many studies in animal skin,[31] individual human skin biopsies[32] and human 3D skin models.[33] The research revealed association with increased sythesis of collagen, elastin, and other extracellular matrix components with changes in growth factors expression. The effectiveness of microneedle mesotherapy on patients was evaluated in El-Domyati et al's studies. They observed clinical and histological improvement of photoaged skin, involved in increased synthesis of collagen types I, III, and VII, increased level of tropoelastin and reduction of solar elastosis, after six microneedling procedures.[34]

It is supposed that we achieved better results in case of combined treatment than the one with peeling only, for the sake of synergistic antiaging activity of two different techniques. The combination of both skin needling and ferulic acid peeling application, significantly enhance their efficacy.

Combining two different low-invasive procedures allows to achieve their additive effects without long postoperative period and risk of persistent side effects. Laws et al and Rawlins et al demonstrated that invasive procedures, including deep epidermal damage, lead to extensive inflammation, and abnormalities in newly synthesized collagen network. It can contribute to greater future susceptibility to skin photodamage.[35,36] In our study, we reported only transient adverse events as pruritus, erythema, burning sensation, and scaling. Our participants did not report true complications. It allows to qualify both ferulic acid peel and combination of ferulic acid with microneedling as a novel, not invasive, and effective techniques of facial photoaging.

5 | CONCLUSIONS

This study demonstrated that the application of ferulic acid peel has moisturizing, melanin and erythema-reducing and elasticity improving effect on human skin. Combining it with microneedle mesotherapy gave slightly better improvement in reducing signs of photoaging, especially in relation to skin elasticity. Furthermore, the treatments were very well tolerated, which made return to normal daily life possible, directly after each session.

ACKNOWLEDGMENTS

This work was supported by statutory research activity of the Department of Cosmetology and Aesthetic Dermatology, Faculty of Pharmacy, Medical University of Lodz, No. 503/3-066-01/503-31-001 and Grant/Award number 502-03/3-066-01/502-34-102.

CONFLICT OF INTEREST

The authors declare no conflict of interest. The authors themselves are responsible for the content and writing of the paper.

ORCID

Master Zduńska-Pęciak Kamila https://orcid.org/0000-0002-3012-9054

REFERENCES

1. Rittie L. UV-light-induced signal cascades and skin aging. *Ageing Research Reviews*. 2002;1(4):705-720. http://dx.doi.org/10.1016/s1568-1637(02)00024-7.
2. Zduńska K, Dana A, Kolodziejczak A, Rotsztejn H. Antioxidant properties of Ferulic acid and its possible application. *Skin Pharmacol Physiol*. 2018a;31:332-336.
3. Nile SH, Ko EY, Kim DH, Keum YS. Screening of ferulic acid related compounds as inhibitors of xanthine oxidase and cyclooxygenase-2 with anti-inflammatory activity. *Rev Brasil Farm*. 2016;26:50-55.
4. Ogiwara T, Satoh K, Kadoma Y, et al. Radical scavenging activity and cytotoxicity of ferulic acid. *Anticancer Res*. 2002;22:2711-2717.
5. Kanski J, Aksenova M, Stoyanova A, Butterfield DA. Ferulic acid antioxidant protection against hydroxyl and peroxyl radical oxidation in synaptosomal and neuronal cell culture systems in vitro: structure-activity studies. *J Nutr Biochem*. 2002;13:273-281.
6. Staniforth V, Huang W, Aravindaram K, Yang N. Ferulic acid, a phenolic phytochemical, inhibits UVB-induced matrix metalloproteinases in mouse skin via posttranslational mechanisms. *J Nutrition Biochem*. 2012;23:443-451.
7. Kwak CS, Yang J. Prevention effect of *Prunus persica* flos extract from reactive oxygen species generation and matrix metalloproteinases production induced by UVB irradiation in human skin cells. *Asian J Beauty Cosmetol*. 2016;14:179-190.
8. Saija A, Tomaino A, Cascio RL, et al. Ferulic and caffeic acids as potential protective agents against photooxidative skin damage. *J Sci Food Agric*. 1999;79:476-480.
9. Hahn H, Kim K, Bae S. Pretreatment of ferulic acid protects human dermal fibroblasts against ultraviolet a irradiation. *Ann Dermatol*. 2016;28(6):740-748.
10. Oresajo C, Stephens T, Hino P. Protective effects of a topical antioxidant mixture containing vitamin C, Ferulic acid, and Phloretin against ultraviolet-induced Photodamage in human skin. *J Cosmet Dermatol*. 2008;7(4):290-297.
11. Pluemsamran T, Onkoksoong T, Panich U. Caffeic acid and ferulic acid inhibit UVA-induced matrix metalloproteinase-1 through regulation of antioxidant defense system in keratinocyte HaCaT cells. *Photochemistry Photobiol*. 2012;88:961-968.
12. Zhou B, Yin H, Xu Y. Baicalin protects human skin fibroblasts from ultraviolet a radiation-induced oxidative damage and apoptosis. *Free Radic Res*. 2012;46(12):1458-1471.

13. Zduńska K, Kołodziejczak A, Rotsztejn H. Is skin microneedling a good alternative method of various skin defects removal. *Dermatologic Therapy*. 2018;31(6):e12714. http://dx.doi.org/10.1111/dth.12714.
14. Bezerra G, Pereira M, Ostrosky E, et al. Compatibility study between ferulic acid and excipients used in cosmetic formulations by TG/DTG, DSC and FTIR. *J Therm Anal Calorim*. 2017;127:1683-1691.
15. Tee-ngam P, Nunant N, Rattanarat P, Siangproh W, Chailapakul O. Simple and rapid determination of ferulic acid levels in food and cosmetic samples using paper-based platforms. *Sensors*. 2013;13:13 039-13 053.
16. Park E, Na JI, Kim SO. Application of a pigment measuring device-Mexameter-for the differential diagnosis of vitiligo and nevus depigmentosus. *Skin Res Technol*. 2006;12(4):298-302.
17. Heinrich U, Koop U. Multicentre comparison of skin hydration in terms of physical, physiological and product-dependent parameters by the capacitance method (Corneometer CM 825). *Int J Cosmet Sci*. 2003;25:45-51.
18. Krueger N, Luebberding S, Oltmer M. Age-related changes in skin mechanical properties: a quantitative evaluation of 120 female subjects. *Skin Res Technol*. 2011;17:141-148.
19. Fisher GJ, Kang SW, Varani J. Mechanisms of photoaging and chronological skin aging. *Arch Dermatol*. 2002;138:1462-1470.
20. Rabe JH, Mamelak AJ, McElgunn PJ, Morison W, Sauder D. Photoaging: mechanisms and repair. *J Am Acad Dermatol*. 2006;55:1-19.
21. Pillai S, Oresajo C, Hayward J. Ultraviolet radiation and skin aging: roles of reactive oxygen species, inflammation and protease activation, and strategies for prevention of inflammation-induced matrix degradation—a review. *Int J Cosmet Sci*. 2005;27:17-34.
22. Lodovici M, Guglielmi F, Meoni M, Dolara P. Effect of natural phenolic acids on DNA oxidation in vitro. *Food Chem Toxicol*. 2001;39:1205-1210.
23. Rice-Evans CA, Miller NJ, Paganga G. Structure-antioxidant activity relationships of flavonoids and phenolic acids. *Free Radic Biol Med*. 1996;20:933-956.
24. Rice-Evans CA, Miller NJ, Paganga G. Antioxidant properties of phenolic compounds. *Trends Plant Sci*. 1997;2:152-159.
25. Kiewlicz J, Szymusiak H, Zieliński R. Thermal stability and antioxidant activity of long-chain alkyl esters od ferulic acid. *Food Sci Technol*. 2015;4:188-200.
26. Shasha H, Yuhong G, Jingxia Z, et al. Ferulic acid protects against heat stress-induced intestinal epithelial barrier dysfunction in IEC-6 cells via the PI3K/Akt-mediated Nrf2/HO-1 signaling pathway. *Int J Hyperthermia*. 2018;35:112-121.
27. El-Domyati M, Medhat W. Minimally invasive facial rejuvenation: current concepts and future expectations. *Expert Rev Dermatol*. 2013;8:565-580.
28. Markiewicz A, Zasada M, Erkiert-Polguj A, Wieckowska-Szakiel M, Budzisz E. An evaluation of the antiaging properties of strawberry hydrolysate treatment enriched with L-ascorbic acid applied with microneedle mesotherapy. *Journal of Cosmetic Dermatology*. 2019;18(1):129-135. http://dx.doi.org/10.1111/jocd.12545.
29. El-Domyati M, Abdel-Wahab H, Hossam A. Combining microneedling with other minimally invasive procedures for facial rejuvenation: a split-face comparative study. *Int J Dermatol*. 2018;57(11):1324-1334.
30. Hye-Jin P, Jun-Hyo C, Shin-Hyub H, et al. Whitening and anti-wrinkle activities of ferulic acid isolated from *Tetragonia tetragonioides* in B16F10 melanoma and CCD- 986sk fibroblast cells. *J Nat Med*. 2018;72:127-135.
31. Zeitter S, Sikora Z, Jahn S, Stahl F, Strauss S, Lazaridis A. Microneedling: matching the results of medical needling and repetitive treatments to maximize potential for skin regeneration. *Burns J Int Soc Burn Injuries*. 2014;40(5):966-973.
32. Helbig D, Mobius A, Simon JC, Paasch U. Heat shock protein 70 expression patterns in dermal explants in response to ablative fractional phothothermolysis, microneedle, or scalpel wounding. *Wounds*. 2011;23(3):59-67.
33. Schmitt L, Marquardt Y, Amann P, Heise R, Huth L, Wagner-Schiffler S. Comprehensive molecular characterization of microneedling therapy in a human three dimensional skin model. *PLoS One*. 2018;13(9):e0204318.
34. El-Domyati M, Barakat M, Awad S, Medhat W, El Fakahany H, Farag H. Multiple microneedling sessions for minimally invasive facial rejuvenation: an objective assessment. *Int J Dermatol*. 2015;54:1361-1369.
35. Laws RA, Finley EM, McCollough ML, Grabski WJ. Alabaster skin after carbon dioxide laser resurfacing with histologic correlation. *Dermatol Surg*. 2012;26:137-140.
36. Rawlins JM. Quantifying collagen type in mature burn scars: a novel approach using histology and digital image analysis. *J Burn Care Res*. 2006;27:60-65.

How to cite this article: Kamila M-P, Helena R. The effectiveness of ferulic acid and microneedling in reducing signs of photoaging: A split-face comparative study. *Dermatologic Therapy*. 2020;33:e14000. https://doi.org/10.1111/dth.14000

Received: 10 October 2021 | Revised: 26 November 2021 | Accepted: 5 December 2021
DOI: 10.1111/dth.15254

ORIGINAL ARTICLE

DERMATOLOGIC THERAPY WILEY

Two superior antioxidants: Ferulic acid and ascorbic acid in reducing signs of photoaging—A split-face comparative study

Kamila Zduńska-Pęciak | Anna Kołodziejczak | Helena Rotsztejn

Department of Cosmetology and Aesthetic Dermatology, Faculty of Pharmacy, Medical University of Łódź, Łódź, Poland

Correspondence
Kamila Zduńska-Pęciak, Department of Cosmetology and Aesthetic Dermatology, Faculty of Pharmacy, Medical University of Łódź, Muszyńskiego 1 Street, PL-91-151 Łódź, Poland.
Email: kamila.zdunska@stud.umed.lodz.pl

Funding information
Statutory research activity of the Department of Cosmetology and Aesthetic Dermatology, Faculty of Pharmacy, Medical University of Lodz, Grant/Award Number: 503/3-066-01/503-31-001; Medical University of Łódź, Grant/Award Number: 502-03/3-066-01/502-34-102

Abstract

The assessment of the signs of photoaging in mexametric (melanin and erythema index), corneometric (hydration level), and cutometric (elasticity) examination after the treatment with ascorbic acid and ferulic acid. This study was conducted in a group of 20 women aged 39–61 (mean age 54), with Fitzpatrick skin types II and III. The study included a series of eight treatments performed once a week. Two layers of peeling, based on 14% ferulic acid (left half of the face) and 12% L-ascorbic acid serum (right half of the face) were applied. To determine skin parameters: moisture, elasticity, melanin level, and erythema intensity, the Multi Probe Adapter Systems (Courage + Khazaka electronic GmbH, Köln, Germany) were used. Additionally, before and after the series of treatments, photographs were taken with the standardized photographic system Fotomedicus (Elfo®). The results of mexametric measurement for melanin level and erythema intensity were statistically significant ($p < 0.0001$) for both acids. Slightly greater lightening of the skin was demonstrated for ascorbic acid. The results of corneometric measurement of hydration level for ferulic acid and ascorbic acid were both statistically significant ($p < 0.0001$). First beneficial changes in improved elasticity could be observed as early as after 8 weeks but the increase in flexibility grew with time (after 12 weeks). These changes affected both acids and all measurement points. The changes in parameters were highly statistically significant ($p < 0.0001$). Based on the conducted research, it is not possible to state which of the tested acids is more effective in reducing the symptoms of photoaging. Both acids (ascorbic and ferulic), which have a high antioxidant potential, affect the measurable parameters of the skin: pigmentation (melanin index), erythema (erythema index), skin hydration, and elasticity.

KEYWORDS
antioxidant, ascorbic acid, chemical peel, ferulic acid, photoaging

1 | INTRODUCTION

In the modern cosmetics industry, both synthetic and natural antioxidants are widely used.[1] Photoaging is one of the processes taking place in the skin, in which the use of antioxidants seems to be crucial.[2] The production of free radicals, initiated mainly by UV radiation, leads to the damage of many skin cells and components, that is, fibroblasts, keratinocytes, collagen, and elastin. Clinical symptoms of skin photodamage are: wrinkles, solar elastosis, loss of elasticity, hyperpigmentation, skin erythema, and keratosis.[3] Antioxidants are able to interrupt a chain reaction of free radical production. This way they protect important vital molecules.[4] Due to their preventive and therapeutic effects, these compounds are widely used in the cosmetic industry, including both: cosmetic products and professional treatments.

 © 2021 Wiley Periodicals LLC.

One of the best known and mainly used antioxidant is vitamin C, and its biologically active form-L-ascorbic acid (AA). With regard to skin, its anti-aging, brightening, strengthening blood vessels and hydrating activity is very well studied.[5] Ascorbic acid is commonly used in cosmetics, most often in skincare products dedicated to photoaging skin as well as with hyperpigmentation and also to skin with erythema.

Ferulic acid (FA) is a good example of another antioxidant with high antioxidative potential. It has proved anti-inflammatory,[6] anticancer,[7] antibacterial,[8] and many other activities. In the cosmetic industry, it is mainly used in sunscreens and anti-aging products, as it exerts brightening, moisturizing and anti-wrinkle effects on the skin.[9,10] To the best of our knowledge, there are only a few studies of the FA effect on human skin with the participation of probands. Most of the research includes cell cultures of fibroblasts, keratinocytes, and melanocytes.[11–13] As it is a novel and very promising antioxidant, we decided to compare its efficiency with well-studied vitamin C. Both compounds are considered to be effective active ingredients in the fight against photoaging. They have long been used synergistically, as FA increases the stability, effectiveness, and photoprotective efficacy of vitamin C, but there is no study comparing these two antioxidants on human skin, so far.[14,15] Therefore we did a split-face study, in which the whitening, moisturizing, erythema-reducing, and firming effect of FA and vitamin C, was examined.

2 | MATERIALS AND METHODS

2.1 | Materials

This study was conducted in a group of 20 women aged 39–61 (mean age 54), with Fitzpatrick skin types II and III. According to Glogau Wrinkle Scale, 2 of them were classified as mild, 15 as moderate, and 3 as advanced facial photoaging. Exclusion criteria included pregnancy, skin diseases, frequent allergic reactions to cosmetic products, taking part in other cosmetic and dermatological procedures during our study, and patients unable to perform necessary postoperative care.

2.2 | Methods

The study included a series of eight treatments performed once a week. The first step was to remove make-up with cleansing milk and then degrease the skin with alcohol-based spray. Afterward, the entire face was sprayed with a special product containing empty nanosomes, preparing skin for the procedure and enhancing transepidermal permeation of active ingredients. Then, two layers of peeling, based on 14% FA, were massaged into the skin on the left half of the face. On the right side of the face, two layers of 12% L-ascorbic acid serum was applied. Both products were from Mediderma by Sesderma®. They contain active ingredient (ferulic or ascorbic acid, respectively) and propylene glycol. Participants were asked to wash their faces at home, after 6 h, using a cotton pad soaked in lukewarm water. Both preparations were in nanosome technology and according to the producer's recommendations, had to be left on the skin for a couple of hours. Patients were instructed to use an only delicate, moisturizing cream and then apply broad-spectrum SPF 50+ sunscreen, every morning.

2.3 | Assessment of efficacy

In this study, The Multi Probe Adapter Systems (Courage + Khazaka electronic GmbH, Köln, Germany) were used to determine skin parameters: moisture (Corneometer), melanin level, and erythema intensity (Mexameter), and elasticity (Cutometer). All measurements were conducted in a measurement room with constant temperature (20°C ± 2°C) and humidity (45% ± 5%) conditions after 20 min patients acclimatization.

All parameters were measured in three points: 1—on the forehead, 2—on the cheek, and 3—on the jaw. The recorded result is the average of three measurements done in each place. Three measurement time-points were established: I-before the treatment, II-directly after the series of treatments, and III-1 month after the last treatment. Additionally, before and after the series of treatments, photographs were taken with the standardized photographic system Fotomedicus (Elfo®).

3 | RESULTS

3.1 | Statistical methods

The mean and SD (mean ± SD) was applied as appropriate for the description of parameters with normal distribution. The not normally distributed variables were expressed as the median and interquartile range (25%; 75%). The Shapiro–Wilk test was used to assume the normality. For statistical evaluation of differences in skin parameters over time, the one-way repeated measures analysis of variance (with a Greenhouse–Geisser sphericity correction when appropriate) followed by Bonferroni post hoc tests were performed. The Mann–Whitney test was used to compare the differences in percentage changes of skin parameters (according to the baseline values) between FA and the ascorbic acid group.

The results of the mexametric (Table 1) measurement of MELANIN (melanin level) for FA (left side of the face) and ascorbic acid (right side of the face) were both statistically significant ($p < 0.0001$). In the case of FA, in all measured points, the most significant changes occurred after the 8 weeks. A reduction in the intensity of skin pigmentation was observed (−17,1%; − 22,2%; − 18.7%), compared to the initial state. Although statistically insignificant ($p = 0.718$; $p = 0.602$; $p = 0.289$), in relation to FA, but greater lightening of the skin was demonstrated for ascorbic acid. The reduction in skin pigmentation was greatest on the cheek (−24.7%).

The results of mexametric (Table 2) measurement of ERYTHEMA (severity of erythema) for FA (left side of the face) and ascorbic acid

TABLE 1 MELANIN parameters according to place and time of measurement

Treatment	Measurement place	Period of study			p value
		Base (*)	After 8 weeks (#)	After 12 weeks	
Ferulic acid (Left)	I (Forehead)	137.8 ± 26.7	***111.3 ± 27.2 −17.1% (−26.3; −15.3)	***120.1 ± 28.7### −13.4% (−19.2; −7.8)	$p < 0.0001$
	II (Cheek)	121.4 ± 25.8	***93.3 ± 26.0 −22.2% (−28.9; −17.3)	***103.8 ± 24.0## −13.1% (−17.5; −11.1)	$p < 0.0001$
	III (Jaw)	139.1 ± 24.4	***114.0 ± 23.1 −18.7% (−21.4; −13.4)	***122.1 ± 23.0## −12.9% (−17.2; −5.6)	$p < 0.0001$
Ascorbic acid (Right)	I (Forehead)	141.0 ± 25.1	***114.8 ± 24.4 −19.7% (−24.0; −13.7) ($p = 0.718$)[a]	***123.0 ± 26.9### −13.4% (−18.8; −9.0) ($p = 0.947$)[a]	$p < 0.0001$
	II (Cheek)	117.4 ± 25.3	***88.2 ± 23.0 −24.7% (−30.6; −18.8) ($p = 0.602$)[a]	***97.7 ± 24.9## −15.3% (−25.4; −8.8) ($p = 0.583$)[a]	$p < 0.0001$
	III (Jaw)	141.5 ± 27.4	***113.0 ± 24.8 −19.4% (−23.4; −17.1) ($p = 0.289$)[a]	***118.6 ± 22.4# −17.0% (−21.3; −10.7) ($p = 0.108$)[a]	$p < 0.0001$

Note: Data presented as mean ± SD or median with IQR (25%; 75%). Percentage value reflects the changes of parameter from baseline. % Versus base.
[a]Versus ferulic acid.
*/#$p < 0.05$ versus base/8 weeks.
**/##$p < 0.01$ versus base/8 weeks.
***/###$p < 0.001$ versus base/8 weeks.

TABLE 2 ERYTHEMA parameters according to place and time of measurement

Treatment	Measurement place	Period of study			p value
		Base (*)	After 8 weeks (#)	After 12 weeks	
Ferulic acid (Left)	I (Forehead)	293.4 ± 55.4	***246.0 ± 47.8 −16.1% (−19.1; −11.8)	***252.8 ± 49.0 −12.9% (−18.7; −8.9)	$p < 0.0001$
	II (Cheek)	311.8 ± 53.5	***268.5 ± 54.8 −13.8% (−19.9; −8.4)	***281.3 ± 50.6## −7.7% (−14.1; −5.9)	$p < 0.0001$
	III (Jaw)	293.3 ± 45.4	***249.5 ± 50.6 −13.8% (−18.1; −10.7)	***261.2 ± 49.0# −10.4% (−15.2; −7.9)	$p < 0.0001$
Ascorbic acid (Right)	I (Forehead)	313.2 ± 47.0	**257.1 ± 72.2 −14.0% (−18.3; −12.1) ($p = 0.478$)[a]	***274.8 ± 51.4 −10.3% (−15.0; −6.9) ($p = 0.289$)[a]	$p = 0.001$
	II (Cheek)	313.8 ± 45.1	***268.9 ± 47.0 −14.7% (−17.9; −12.2) ($p = 0.968$)[a]	***281.9 ± 49.9## −9.9% (−13.9; −6.6) ($p = 0.620$)[a]	$p < 0.0001$
	III (Jaw)	283.8 ± 40.5	***246.6 ± 35.2 −12.8% (−18.7; −10.6) ($p = 0.820$)[a]	***257.8 ± 43.1# −9.6% (−13.4; −4.4) ($p = 0.314$)[a]	$p < 0.0001$

Note: Data presented as mean ± SD or median with IQR (25%; 75%). Percentage value reflects the changes of parameter from baseline. % Versus base.
[a]Versus ferulic acid.
*/#$p < 0.05$ versus base/8 weeks.
**/##$p < 0.01$ versus base/8 weeks.
***/###$p < 0.001$ versus base/8 weeks.

(right side of the face) were both statistically significant ($p < 0.0001$). Analyzing the statistical percentage reduction, it is slightly smaller than in the case of the MELANIN. For FA: −16.1%; −13.8%; −13.8% and for ascorbic acid: −14.0%; −14.7%; −12.8% after 8 weeks.

The results of corneometric (Table 3) measurement of hydration level for FA and ascorbic acid were both statistically significant ($p < 0.0001$). The improvement in skin hydration was significant, reaching as much as 39.3%–76.6% of the baseline value.

Cutometer is used to evaluate biomechanical skin properties. It measures the elasticity of skin using negative pressure which mechanically deforms the skin. R2 is the most common parameter in medical literature used to evaluate skin aging. R2 refers to gross-elasticity of

TABLE 3 CORNEOM parameters according to place and time of measurement

Treatment	Measurement place	Period of study			p value
		Base (*)	After 8 weeks (#)	After 12 weeks	
Ferulic acid (Left)	I (Forehead)	42.6 ± 8.5	***62.2 ± 10.4 52.5% (33.1; 58.0)	***54.9 ± 8.3### 29.8% (16.3; 43.8)	$p < 0.0001$
	II (Cheek)	36.6 ± 12.1	***52.8 ± 14.9 45.8% (31.9; 60.8)	***46.5 ± 14.6### 30.0% (13.3; 41.1)	$p < 0.0001$
	III (Jaw)	36.3 ± 11.5	***53.4 ± 13.6 51.0% (32.4; 72.6)	***46.3 ± 12.6### 29.0% (18.1; 41.1)	$p < 0.0001$
Ascorbic acid (Right)	I (Forehead)	44.9 ± 7.5	***62.4 ± 8.6 39.3% (29.1; 52.2) ($p = 0.242$)[a]	***55.3 ± 8.6### 25.8 (9.1; 38.4) ($p = 0.383$)[a]	$p < 0.0001$
	II (Cheek)	36.2 ± 11.0	***53.5 ± 15.2 52.1 (39.8; 70.0) ($p = 0.445$)[a]	***49.0 ± 14.0## 35.1% (20.9; 50.7) ($p = 0.327$)[a]	$p < 0.0001$
	III (Jaw)	27.9 ± 10.9	***46.1 ± 15.5 76.6% (47.8; 91.8) ($p = 0.020$)[a]	***39.1 ± 14.4### 43.4% (23.0; 66.1) ($p = 0.076$)[a]	$p < 0.0001$

Note: Data presented as mean ± SD or median with IQR (25%; 75%). Percentage value reflects the changes of parameter from baseline. % Versus base.
[a]Versus ferulic acid.
*/#$p < 0.05$ versus base/8 weeks.
**/##$p < 0.01$ versus base/8 weeks.
***/###$p < 0.001$ versus base/8 weeks.

TABLE 4 CUTOMETER parameters according to site and time of measurement

Treatment	Measurement place	Period of study			p value
		Base (*)	After 8 weeks (#)	After 12 weeks	
Ferulic acid (Left)	I (Forehead)	0.436 ± 0.135	***0.543 ± 0.150 22.7% (14.9; 38.8)	***0.578 ± 0.150## 35.1% (22.5; 47.3)	$p < 0.0001$
	II (Cheek)	0.469 ± 0.124	***0.572 ± 0.134 21.2% (14.5; 30.0)	***0.615 ± 0.136## 34.2% (24.4; 42.1)	$p < 0.0001$
	III (Jaw)	0.549 ± 0.135	***0.640 ± 0.140 16.4% (10.1; 22.9)	***0.676 ± 0.142## 20.5% (15.5; 35.3)	$p < 0.0001$
Ascorbic acid (Right)	I (Forehead)	0.432 ± 0.120	***0.587 ± 0.144 39.9% (24.3; 47.8) ($p = 0.049$)[a]	***0.618 ± 0.131 44.4% (29.9; 62.1) ($p = 0.192$)[a]	$p < 0.0001$
	II (Cheek)	0.465 ± 0.133	***0.592 ± 0.144 23.6% (17.7; 44.5) ($p = 0.265$)[a]	***0.628 ± 0.143## 36.9% (25.6; 41.7) ($p = 0.565$)[a]	$p < 0.0001$
	III (Jaw)	0.509 ± 0.115	***0.604 ± 0.130 16.4% (10.0; 26.2) ($p = 0.841$)[a]	***0.653 ± 0.140## 28.9% (17.8; 35.3) ($p = 0.253$)[a]	$p < 0.0001$

Note: Data presented as mean ± SD or median with IQR (25%; 75%). Percentage value reflects the changes of parameter from baseline. %Versus base.
[a]Versus ferulic acid.
*/#$p < 0.05$ versus base/8 weeks.
**/##$p < 0.01$ versus base/8 weeks.
***/###$p < 0.001$ versus base/8 weeks.

the skin. First beneficial changes could be observed as early as after 8 weeks but the increase in flexibility grew with time (after 12 weeks). These changes affected both acids and all measurement points. The change in parameters was highly statistically significant ($p < 0.0001$) (Table 4). The results were better for ascorbic acid ($p < 0.05$) in one measurement point (forehead) and in one time point (after 8 weeks) (Figure 1).

On the basis of the conducted research, it is not possible to state which of the tested acids is more effective in reducing the symptoms of photoaging.

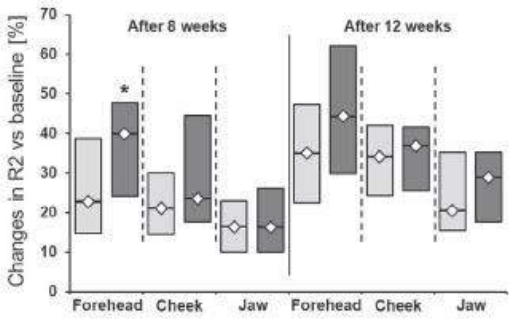

FIGURE 1 R2 values in all measurement and time points. R2 values are expressed as percentage changes from baseline. Data presented as median (horizontal bar with a diamond sign) and lower–upper quartile range (box) for skin treated with either ferulic acid peel-left side (light gray box) or ascorbic acid serum -right side (dark gray box). *$p < 0.05$ versus ferulic acid side

The results achieved by means of using apparatus are reflected in the photographs by the Fotomedicus system (Elfo), taken before and immediately after a series of treatments (Figures 2 and 3).

4 | DISCUSSION

4.1 | Ascorbic acid

Mexameter is a non-invasive device used to measure the concentration of melanin and hemoglobin in the skin. In our study, a reduction in erythema was demonstrated after treatments with vitamin C. This may be due to the fact that applying vitamin C can increase the level of mRNA of collagen III, which is the main ingredient of blood vessel walls.[16] Scientific research confirms that vitamin C affects the appearance of capillary skin.[17] Jaros et al. showed that 5% vitamin C concentrate causes significant erythema reduction ($p < 0.0001$) in capillary skin and photoaging skin. The research was conducted on a group of 30 women. Erythema decreased by: 9% after 2 weeks; 16% after 4 weeks; 21% after 6 weeks. In the control group an increase in the level of erythema by 7% was demonstrated, based on VISIA photograph system (compared to the study group undergoing vitamin C treatment).[16] Sauermann et al. in an in vivo study determined the effect of a topical cream with 3% vitamin C using daily applications for 4 months on the forearms of 33 women. They showed, with the confocal laser scanning microscopy method, that topical vitamin C may have therapeutic effects enhancing the density of dermal papillae, perhaps through the mechanism of angiogenesis.[18] Vitamin C has a protective effect on the endothelium of the blood vessels of the skin plexuses (it determines the maintenance of the mechanical resistance of the capillary walls).

In our study, mexametric measurements demonstrate a statistically significant ($p < 0.0001$) change in skin color toward the reduction of pigmentation after the use of vitamin C. Ascorbic acid reduces the synthesis of melanin (inhibition of the synthesis of tyrosinase). It is effective in lightening the skin of some patients with hyperpigmentation disorders (melasma or solar lentigines). This vitamin C derivative suppresses melanin formation by influencing tyrosinase and melanoma cells. It stimulates the synthesis of ceramides—maintaining proper skin hydration due to the formation of stratum corneum barrier lipids. It seems that ascorbate normalizes epidermal lipid profiles, in particular glucosphingolipids and ceramides.[19,20] Vitamin C protects the nuclei of keratinocytes from damage and changes that lead to the formation of sunburn cells. Humbert et al. performed a double-blind randomized trial to evaluate the skin over a 6-month period of use of a cream witch 5% vitamin C. They were concluded that topical the vitamin C leads to a clinically apparent improvement in the appearance of photodamaged skin. After three and more to 6 months, significant improvement of: moisturizing skin, smoothing the surface, tone of skin, pigmentation (lightening) were observed. The study was based on: assessment by the investigator and volunteers, skin relief measurements (silicone rubber Silflo), and skin biopsies.[21]

The own study showed an improvement in skin elasticity (cutometric measurements). Vitamin C neutralizes free radicals created by the activation of neutrophils, prevents peroxidation processes initiated by free radicals, and suppresses the release of superoxide anions by macrophages. Vitamin C has a protective function for mitochondria. Ascorbic acid, when applied topically, improves the appearance of photoaged skin, protects and reduces the amount of damage caused by UVB radiation. What else, the amount of vitamin C in the skin drops dramatically after UV irradiation.[3] Ascorbic acid affects the activity of fibroblasts and thus participates in the synthesis of collagen, thus the lack of l-ascorbic acid reduces the synthesis of collagen. The inhibition of MMP-1 was proved to decrease wrinkles.[17] Vitamin C has been shown to inhibit the activation of aP-1, which leads to a reduction in MMP production and collagen damage after exposition on UV. Vitamin C inhibits the biosynthesis of elastin.[20,22] It takes part in the process of hydroxylation of proline to 4-hydroxyproline, acting as a co-factor. Hydroxyproline acts to stabilize the collagen triple helix and it is necessary for cross-linking one collagen molecule to another, providing tissue strength.[16,19] It can also affect collagen synthesis by activating its transcription procollagen mRNA. Moreover, as a result of many months using ascorbic acid, type I collagen fibers were more evenly distributed.[21] Visible improvement in the form of reduced depth of nasolabial fold, conducted with the use of Primos, was also observed.[16] Sachs DL et al. observed an increase in collagen (steady-state procollagen I levels) synthesis in subjects with hypo-collagenesis. In contrast, topical vitamin C had no effects on procollagen production in individuals with normo-collagenesis.[23]

4.2 | Ferulic acid

FA has many functions in the skin, so it has been widely used in the cosmetics industry. It is used in skincare formulations as a brightening component, photoprotective agent, and delayer of skin photoaging processes. FA when used as a topical antioxidant maintains a high

FIGURE 2 The efficacy of FA and AA in reducing wrinkles. Before (I photograph). After the series of treatments (II photograph)

FIGURE 3 The efficacy of FA and AA in lightening the skin. Before (I photograph). After the series of treatments (II photograph)

local concentration and has low cutaneous metabolism. It possesses anti-inflammatory and antimicrobial activity, and has a protective role for the fibroblasts and keratinocytes. It induces angiogenesis and inhibits melanogenesis.

Lin et al. in their research conducted using HUVEC-human umbilical vein endothelial cells have shown that FA enhances VEGF and PDGF expression and increases the amount of hypoxia-induced HIF-1, which generates hypoxia-responsive responses.[24,25] Therefore, we can assume FA can affect the formation of new vessels by affecting the activity of the main factors involved in it, that is, PDGF (platelet-derived growth factor) and VEGF (vascular endothelial growth factor). In principle, angiogenesis may reduce the appearance of erythema by reducing vasodilatation. In our study, the effect of reducing the intensity of erythema under the influence of FA was shown.

In our research, using the Mexameter measuring probe, showed a reduction in the intensity of skin pigmentation. It is related with ability of the acid to inhibit the tyrosinase activity and inhibit melanocytic proliferation.[12,26] Second, it fights against ROS which is an important trigger of melanogenesis therefore also prevents DNA damage.[27] In order to intensity of the action of the brightening effect, FA can be combined with a keratolytic agent.[28] Staniforth et al. noted that FA absorbs UV (290–320 nm).[29] It is used in pigmentary disorders like melasma and constitutional type of POH—periorbital hyperpigmentation.[27]

FA can prevent collagen degradation,[30] through the antioxidant effect. FA reduces adverse UV effects if it is administered prior to exposure. Pluemsamran et al. proved that keratinocytes are much less susceptible to free radical damage when exposed to FA before

irradiation. Hahn et al. have shown that intracellular reactive oxygen species production after radiation of UVA[11] and UVB[31] in fibroblasts is lower, after FA application.[11] FA aplicated before exposure to UV causes less ROS production and reduced stimulation of metalloproteinases (MMP-1). In turn, the production of intrinsic antioxidants (glutathione and catalase) increased. Moreover, application of FA prevent from elastosis, as the cause of it are ROS. The increase in tropoelastin mRNA expression in the cells exposed to ROS is known.[32,33] The production of ROS in the skin leads to a decrease in collagen and elastin. This will consequently cause wrinkling, thinning, and loosening of the skin. These findings have brought the important role of antioxidants into perspective. It can be assumed that in our study we have shown the beneficial effect of antioxidants on the mechanical properties of the skin, that is, its elasticity (Cutometer analysis). FA as an antioxidant can provide adequate photoprotection to the skin because it penetrates deep into the skin.[34]

0.5%–1% acid concentration in cosmetic products is used in the production of face masks and protective and moisturizing creams/lotions. In cosmetology and medical aesthetics salons, it is most often used at a concentration of 12% and in combination with vitamins C and hyaluronic acid. In their research, the authors were shown the effect of increasing skin hydration after treatment with FA. To improve efficiency of FA it is combined with the microneedling procedure. What is more, FA was found to permeate through the stratum corneum, regardless of pH value. The ability to cross the dermal barrier could be a challenge for some antioxidants. This difficulty is explained by the distinct composition of the different skin layers.

5 | CONCLUSION

Both acids (ascorbic and ferulic), which have a high antioxidant potential, affect the measurable parameters of the skin: pigmentation (melanin index), erythema (erythema index), skin hydration, and elasticity. The effectiveness of both substances in reducing signs of photoaging is very similar. We observed slightly greater lightening of the skin for ascorbic acid than for FA, but these differences were statistically insignificant.

ACKNOWLEDGMENTS

This work was supported by statutory research activity of the Department of Cosmetology and Aesthetic Dermatology, Faculty of Pharmacy, Medical University of Lodz, No. 503/3-066-01/503-31-001 and Grant/Award number 502-03/3-066-01/502-34-102.

CONFLICT OF INTEREST

The authors declare no conflicts of interest.

ETHICS STATEMENT

All participants have given their written informed consent to the procedure. The study protocol has been approved by the Bioethics Committee of the Medical University of Lodz (Protocol No. RNN/81/19/KE). All procedures involving human probands were in accordance with the ethical standards of the institutional and/or national research committee and with the 1964 Helsinki declaration and its later amendments or comparable ethical standards.

DATA AVAILABILITY STATEMENT

The data that support the findings of this study are available from the corresponding author upon reasonable request.

ORCID

Kamila Zduńska-Pęciak https://orcid.org/0000-0002-3012-9054
Anna Kołodziejczak https://orcid.org/0000-0002-7799-9188

REFERENCES

1. Permana AD, Utami RN, Courtenay AJ, Manggau MA, Donnelly RF, Rahman L. Phytosomal nanocarriers as platforms for improved delivery of natural antioxidant and photoprotective compounds in propolis: an approach for enhanced both dissolution behaviour in biorelevant media and skin retention profiles. *J Photochem Photobiol*. 2020;205:111846.
2. Pisoschi AM, Pop A. The role of antioxidants in the chemistry of oxidative stress: a review. *Eur J Med Chem*. 2015;97:55-74.
3. Augustyniak AM, Rotsztejn H, Bartnicka E, Budzisz E. Effects of reactive oxygen species on skin photoaging. *Przegl Dermatol*. 2016;103:233-239.
4. Oroian M, Escriche I. Antioxidants: characterization, natural sources, extraction and analysis. *Food Res Int*. 2015;74:10-36.
5. Thomas JR, Dixon TK, Bhattacharyya TK. Effects of topicals on the aging skin process. *Facial Plast Surg Clin North Am*. 2013;21:55-60.
6. Barone E, Calabrese V, Mancuso C. Ferulic acid and its therapeutic potential as a hormetin for age-related diseases. *Biogerontology*. 2009;10:97-108.
7. Alias LM, Manoharan S, Vellaichamy L, Balakrishnan S, Ramachandran CR. Protective effect of ferulic acid on 7,12-dimethylbenz[a] anthracene-induced skin carcinogenesis in swiss albino mice. *Exp Toxicol Pathol*. 2009;61:205-214.
8. Van der Watt E, Pretorius JC. Purification and identification of active antibacterial components in Carpobrotus edulis L. *J Ethnopharmacol*. 2001;76:87-91.
9. Kwak CS, Yang J. Prevention effect of Prunus persica flos extract from reactive oxygen species generation and matrix metalloproteinases production induced by UVB irradiation in human skin cells. *Asian J Beauty Cosmetol*. 2016;14:179-190.
10. Saija A, Tomaino A, Cascio RL, et al. Ferulic and caffeic acids as poten- tial protective agents against photooxidative skin damage. *J Sci Food Agric*. 1999;79:476-480.
11. Hahn H, Kim K, Bae S. Pretreatment of ferulic acid protects human dermal fibroblasts against ultraviolet a irradiation. *Ann Dermatol*. 2016;28:740-748.
12. Oresajo C, Stephens T, Hino P. Protective effects of a topical antioxidant mixture containing vitamin C, ferulic acid, and phloretin against ultraviolet-induced photodamage in human skin. *J Cosmet Dermatol*. 2008;7:290-297.
13. Pluemsamran T, Onkoksoong T, Panich U. Caffeic acid and ferulic acid inhibit UVA-induced matrix metalloproteinase-1 through regulation of antioxidant defense system in keratinocyte HaCaT cells. *Photochem Photobiol*. 2012;88:961-968.
14. Lin F-H, Lin J-Y, Ravindra D, et al. Ferulic acid stabilizes a solution of vitamins C and E and doubles its photoprotection of skin. *J Invest Dermatol*. 2005;125:826-832.
15. Murray JC, Burch JA, Streilein RD, Iannacchione MA, Hall RP, Pinnell SR. A topical antioxidant solution containing vitamins C and E stabilized by ferulic acid protects human skin against damage caused by ultraviolet irradiation. *J Am Acad Dermatol*. 2008;59:418-425.

16. Jaros A, Zasada M, Budzisz E, Dębowska R, Gębczyńska-Rzepka M, Rotsztejn H. Evaluation of selected skin parameters following the application of 5% vitamin C concentrate. *J Cosmet Dermatol*. 2019;18:236-241.
17. Korać RR, Khambholja KM. Potential of herbs in skin protection from ultraviolet radiation. *Pharmacogn Rev*. 2011;5:164-173.
18. Sauermann K, Jaspers S, Koop U, Wenck H. Topically applied vitamin C increases the density of dermal papillae in aged human skin. *BMC Dermatol*. 2004;29:13.
19. Humbert P, Messikh R, Try C. The action of vitamin C for treating wrinkles and protecting skin from photodamage. *Eur Dermatol*. 2010;5:36-40.
20. Burke KE. Interaction of vitamins C and E as better cosmeceuticals. *Dermatol Ther*. 2007;20:314-321.
21. Humbert PG, Haftek M, Creidi P, et al. Topical ascorbic acid on photoaged skin. Clinical, topographical and ultrastructural evaluation: double-blind study vs. placebo. *Exp Dermatol*. 2003;12:237-244.
22. Al-Niaimi F, Chiang NYZ. Topical vitamin C and the skin: mechanisms of action and clinical applications. *J Clin Aesthet Dermatol*. 2017;10:14-17.
23. Sachs DL, Rittié L, Chubb HA, Orringer J, Fisher G, Voorhees JJ. Hypo-collagenesis in photoaged skin predicts response to anti-aging cosmeceuticals. *J Cosmet Dermatol*. 2013;12:108-115.
24. Yang G, Jiang J, Lu W. Ferulic acid exerts anti-angiogenic and anti-tumor activity by targeting fibroblast growth factor receptor 1-mediated angiogenesis. *Int J Mol Sci*. 2015;16:24011-24031.
25. Lin C, Chiu J, Wu I, Wang B, et al. Ferulic acid augments angiogenesis via VEGF, PDGF and HIF-1 alpha. *J Nutr Biochem*. 2010;21:627-633.
26. Murray JC, Burch JA, Streilein RD, Iannacchione MA, Hall RP, Pinnell SR. A topical antioxidant solution containing vitamins C and E stabilized by ferulic acid provides protection for human skin against damage caused by ultraviolet irradiation. *J Am Acad Dermatol*. 2008;59:418-425.
27. Dayal S, Sangal B, Sahu P. Ferulic acid 12% peel: an innovative peel for constitutional type of periorbital melanosis-comparing clinical efficacy and safety with 20% glycolic peel and 15% lactic peel. *J Cosmet Dermatol*. 2020;19:2342-2348.
28. Saint-Leger D, Leveque JL, Verschoore M. The use of hydroxy acids on the skin: characteristics of C8-lipohydroxy acid. *J Cosmet Dermatol*. 2007;6:59-65.
29. Staniforth V, Huang W, Aravindaram K, Yang N. Ferulic acid, a phenolic phytochemical, inhibits UVB-induced matrix metalloproteinases in mouse skin via posttranslational mechanisms. *J Nutr Biochem*. 2012;23:443-451.
30. Bian Y, Guo J, Majeed H, Zhu K, et al. Ferulic acid renders protection to HEK293 cells against oxidative damage and apoptosis induced by hydrogen peroxide. *In Vitro Cell Dev Biol-Anim*. 2015;51:722-729.
31. Nagarajan RP, Ambothi K. Ferulic acid prevents ultraviolet-B radiation induced oxidative DNA damage in human dermal fibroblasts. *Int J Nutr Pharmacol Neurol Dis*. 2014;4:203.
32. Warren R, Gartstein V, Kligman AM, Montagna W, Allendorf RA, Ridder GM. Age, sunlight, and facial skin: a histologic and quantitative study. *J Am Acad Dermatol*. 1991;25:751-760.
33. Kawaguchi Y, Tanaka H, Okada T, et al. Effect of reactive oxygen species on the elastin mRNA expression in cultured human dermal fibroblasts. *Free Radic Biol Med*. 1997;23:162-165.
34. Mathew S, Abraham ET. Ferulic acid: an antioxidant found naturally in plant cell walls and feruloyl esterases involved in its release and their applications. *Crit Rev Biotechnol*. 2004;24:59-83.

How to cite this article: Zduńska-Pęciak K, Kołodziejczak A, Rotsztejn H. Two superior antioxidants: Ferulic acid and ascorbic acid in reducing signs of photoaging—A split-face comparative study. *Dermatologic Therapy*. 2021;e15254. doi:10.1111/dth.15254

Received: 21 January 2022 | Accepted: 24 April 2022
DOI: 10.1111/dth.15543

ORIGINAL ARTICLE

DERMATOLOGIC THERAPY WILEY

Ferulic acid – A novel topical agent in reducing signs of photoaging

Kamila Zduńska-Pęciak[1] | Renata Dębowska[2] | Anna Kołodziejczak[1] | Helena Rotsztejn[1]

[1]Department of Cosmetology and Aesthetic Dermatology, Faculty of Pharmacy, Medical University of Łódź, Łódź, Poland

[2]Centre for Science and Research Dr Irena Eris, Warsaw, Poland

Correspondence
Kamila Zduńska-Pęciak, Department of Cosmetology and Aesthetic Dermatology, Faculty of Pharmacy, Medical University of Łódź, Muszyńskiego 1 Street, PL-91-151 Łódź, Poland.
Email: kamila.zdunska@stud.umed.lodz.pl

Funding information
Medical University of Łódz, Grant/Award Numbers: 503/3-066-01/503-31-001, 502-03/3-066-01/502-34-102

Abstract

Continuous production of reactive oxygen species, induced by UV radiation, is one of the main mechanisms contributing to skin photoaging. Therefore, the use of novel superior antioxidants, which ferulic acid belongs to, is an innovative treatment option. The aim of this study was to evaluate the effect of 14% ferulic acid peel on skin hydration, topography, the level of melanin, and the severity of erythema, in people with skin photoaging symptoms. Twenty women aged 45–60, received eight treatments of chemical peeling in 1-week intervals. Efficacy was measured using The Multi Probe Adapter (MPA) Systems (Courage + Khazaka electronic GmbH, Köln, Germany). The measurements were taken before, 8, and 12 weeks after the first treatment. Additionally, the photo documentation was made with Fotomedicus (Elfo) and VISIA® Complexion Analysis System (Canfield Scientific, Inc.). The objective evaluation showed statistically significant improvement in all measured skin parameters $p < 0.05$). The best results of skin hydration and melanin level were observed right after the end of the series ($p < 0.001$). The best improvement in erythema reduction was noted a month after the last treatment ($p < 0.0001$). At the control, untreated point none of the probes showed statistically significant changes. In conclusion, a series of treatments with 14% ferulic acid peel has a significant bleaching, erythema-reducing, and moisturizing activity. The results achieved by apparatus, are reflected by photo documentation. The effects achieved during a series persist over time.

KEYWORDS
antioxidant, chemical peel, ferulic acid, photoaging

1 | INTRODUCTION

Exposure to ultraviolet radiation may contribute to the increase in reactive oxygen species (ROS), which may be connected with all sorts of negative biochemical processes within the skin. The free oxygen radicals are considered to be one of the major causes of elastosis (accumulation of tropoelastin aggregates in photoaging skin).[1] The other signs of photoaging such as wrinkles, dryness, hyperpigmentation, telangiectasia, are also closely related to oxidative stress.[2] On this basis, it is suggested that the strong antioxidant compounds, given either orally or applied topically on the skin, could reduce and prevent the signs of photoaging.

Ferulic acid ([E]-3-[4-hydroxy-3-methoxy-phenyl] prop-2-enoic acid) (Figure 1) is a phenolic antioxidant found in high concentration in plant tissues.[3] In plants, it is biosynthesized from the action of O-methyl transferase on caffeic acid.[4] It has low toxicity and many proven physiological functions (antioxidant,[5] anti-inflammatory,[6] anticancer,[7] antidiabetic,[8] antimicrobial[9]). The most important property of it is its function as an antioxidant. It has been shown to be useful in counteracting skin photoaging because it has the ability to

 © 2022 Wiley Periodicals LLC.

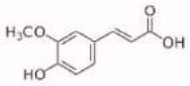

FIGURE 1 Chemical structure of ferulic acid

function as an antioxidant in sunburn cells. Ferulic acid is able to absorb UVA (cis-ferulic acid—peak at 317 nm; trans-ferulic acid—236 and 322 nm).[10] Until recently, this compound was used synergistically together with other antioxidants such as vitamin C and E, increasing their effectiveness and participating in their regeneration processes.[11] After oral administration, the bioavailability of ferulic acid in the skin is relatively low.[12]

Formulas enriched with ferulic acid gain several times higher antioxidant and photoprotective efficacy than those without it. The effectiveness of ferulic acid, as a strong antioxidant reducing UV-induced oxidative skin damage, as well as inhibiting the formation of hyperpigmentation and accelerating skin regeneration, has been proved in numerous studies on cell cultures of fibroblasts, keratinocytes, and melanocytes.[13-16] The results of these studies are promising positive and would qualify ferulic acid as a novel, effective therapeutic agent. However, to our present knowledge, there is a scarcity of studies evaluating the impact of ferulic acid on photoaging skin. The aim of this study is to evaluate the effect of ferulic acid on skin hydration, topography, the level of melanin, and the severity of erythema, in people with skin photoaging symptoms.

2 | MATERIAL AND METHODS

2.1 | Patient selection

The study included a group of 20 patients aged 45–60, with the II and III skin phototypes according to Fitzpatrick's scales. Clinical evaluation of photoaging was done according to Glogau Wrinkle Scale. Fourteen patients were classified as moderate (II type) and six patients as severe (IV type) facial photoaging. Before starting the examination, a detailed interview with each of the patients was conducted. It regarded general health, including information about taken medicines and skin diseases. The patients were qualified for the examination and then instructed about skin care regimen after the treatments. All patients pledged to comply with the recommendations and to resign from other cosmetic and dermatological procedures for the entire duration of the study. Each of the patients completed a full cycle of tests.

2.2 | Treatment protocol

Each patient received a series of eight treatments of chemical peeling based on 14% ferulic acid (Mediderma by Sesderma®), performed once a week. This product contains ferulic acid (in nanosome technology) and propylene glycol. Before applying ferulic peeling, the skin was cleaned with the make-up cleansing milk and then degreased with disinfectant spray based on ethyl alcohol. Next, a special product containing empty nanosomes was sprayed on the face, to enhance the transepidermal permeation of active ingredients. Afterward, in a few minutes intervals, two layers of peeling were applied to the skin. A total of 1.5 ml. Each layer, in accordance with the producer's recommendations, was massaged into the skin until absorbed. Next, patients were asked to wash their faces at home 6 h after the treatment, using a cotton pad soaked in lukewarm water, as the nanosome products had to be left on the skin for a couple of hours. Patients were instructed to use only delicate, moisturizing cream and apply sunscreen with a high Sun Protection Factor (SPF 50) every morning.

2.3 | Measurement

Measurements of selected skin parameters were made with Mexameter (melanin and erythema level) and Corneometer (skin hydration level)—The Multi Probe Adapter (MPA) Systems (Courage + Khazaka electronic GmbH, Köln, Germany). The measurements included 3-time points: before starting a series of treatments, immediately after the end of the series (8 weeks after the first treatment), and 1 month after the end of the series (12 weeks after the first treatment). Three measurement points were designated: 1—on the forehead, 2—on the cheek, and 3—on the jaw. The untreated skin sample behind the ear constituted a control point (point 4), as it is the nearest and most similar skin area to the treated one. All measurements were done three times in each place and the recorded result is their average.

All measurements were made in the same room, with constant temperature conditions (24–26°C) and air humidity (33%–41%), always at a similar time of the day. Before taking the measurements, the patients were asked for 10–15 min acclimatization in the measuring room.

Mexameter MX 18 (Courage + Khazaka electronic) it is a non-invasive device used to measure the concentration of melanin and hemoglobin in the skin by light absorption. The probe emits light at three wavelengths selected to achieve different levels of absorption by the pigment melanin (MEX) and hemoglobin (ERYT). The amount of light emitted is precisely defined, the amount of light absorbed by the skin can be calculated and the receptor measures the light reflected from the skin. Melanin and erythema index were calculated.

Skin hydration was measured with Corneometer CM825, which measurement of skin's electrical capacity, based on the relatively high dielectric constant of water. It is related to the degree of epidermal hydration. Parameters used: skin compressed for 1 s with a force of 7.1 N/cm^2, 20–30 μm deep into the stratum corneum. The measurement result is in the range 0–130. The higher is the value, the better is the hydration of the epidermis.

The topography of the skin was accurately examined with Visioscan® VC 98 (Courage + Khazaka electronic GmbH, Köln, Germany)—a high-resolution UVA camera. The photographs show the

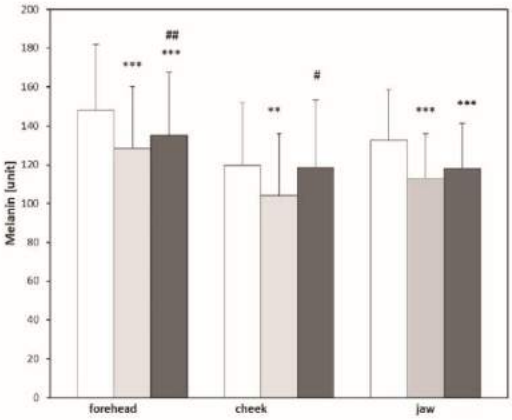

FIGURE 2 Melanin value according to place and time of measurement. White bar—measurement I, light gray bar—measurement II, dark gray bar—measurement III. Data presented as mean ± SD. ***$p < 0.0001$; **$p < 0.01$ versus measurement I; ##$p < 0.01$; #$p < 0.05$ versus measurement II

structure of the skin in multiple magnifications. The SELS® parameters (Surface Evaluation of the Living Skin), developed especially for this camera are SEsc (scaliness)—a value expressed in arbitrary units, showing the level of exfoliation of the stratum corneum, including the value of hydration and SEr—skin roughness. Both values increase with age.

Additionally, before starting the treatment and after its completion, photographs were taken with photographic systems: VISIA® Complexion Analysis System (Canfield Scientific, Inc.) and Fotomedicus (Elfo®).

3 | RESULTS

The results are presented as mean value and standard deviation (SD) mean ± SD. Repeated measures one-way analysis of variance (ANOVA) (with a Greenhouse–Geisser correction where appropriate) followed by Bonferroni's post hoc comparisons tests were used.

3.1 | Skin lightening efficacy

A statistically significant difference in skin melanin level was observed in all measuring points, directly after a series of treatments. The decrease of melanin level was slightly greater on the forehead and on the jaw than on the cheek area ($p < 0.0001$ and $p < 0.001$, respectively) (Figure 2). The last measurement, taken a month after the end of the series, showed still a significant improvement on the forehead and jaw, compared to the baseline ($p < 0.0001$). On the cheek, the level of melanin raised almost to the baseline a month after the series of treatments.

3.2 | Anti-redness efficacy

At the end of the series, the intensity of erythema decreased significantly in all measuring points, showing slightly greater efficacy on the forehead ($p < 0.0001$) than on the cheek and jawline ($p < 0.05$). A month after the series of treatments the improvement was even better, showing statistical significance of $p < 0.0001$ on the forehead and $p < 0.001$ on the cheek and jaw areas (Figure 3).

3.3 | Skin hydrating efficacy

A statistically significant difference in skin hydration level was observed in all measuring points, directly after a series of treatments ($p < 0.0001$). A month after the end of the series, hydration decreased slightly, compared to the second measurement, still showing the statistically significant difference to the baseline ($p < 0.0001$ on the cheek and jaw and $p < 0.001$ on the forehead) (Figure 4).

3.4 | Skin smoothing efficacy

Statistically significant reduction of exfoliation (SEsc) and roughness (SEr) of the epidermis, was observed on the forehead and jaw ($p < 0.05$) (Table 1).

At the control, untreated point none of the probes showed statistically significant changes (Table 2).

Throughout the duration of the study, none of the patients' side effects were noted in the form of irritation, burning, redness of the skin, which proves the safety of using ferulic acid in the form of chemical peeling.

4 | DISCUSSION

Photoaging of the skin is a process that affects both: the epidermis and the dermis. Histologically, in the epidermis, it concerns its thickening and alterations within its cells (i.e. melanocytes and Langerhans cells). However, major changes are observed in the dermis and they relate to the elastosis process, the invalid structure of collagen fibers, changes in the number of proteoglycans, glycosaminoglycans, and inflammatory cells.[2] Therefore, for the treatment of photoaging skin, a substance that penetrates into the deeper tissue is needed.[17] Ferulic acid has been shown to penetrate deeply into the skin, both acidic and neutral pH, in dissociated and non-dissociated forms. Its efficiency is closely related to maintaining a high local concentration and low cutaneous metabolism.[17-19]

This study demonstrated, that ferulic acid peel is an effective therapeutic agent in reducing clinical signs of photoaging such as skin dryness, telangiectasia, erythema, and hyperpigmentation. The results achieved by MPA probes (Mexameter and Cutometer) are reflected by photo documentation (Figures 5 and 6).

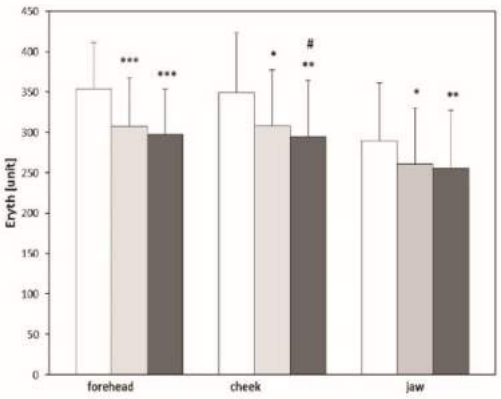

FIGURE 3 Erythema value according to place and time of measurement. White bar—measurement I, light gray bar—measurement II, dark gray bar—measurement III. Data presented as mean ± SD. ***$p < 0.0001$; **$p < 0.01$; *$p < 0.05$ versus measurement I; #$p < 0.05$ versus measurement II

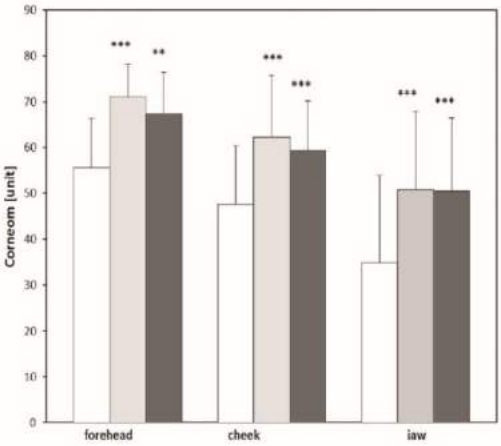

FIGURE 4 Skin hydration level according to place and time of measurement. White bar—measurement I, light gray bar—measurement II, dark gray bar—measurement III. Data presented as mean ± SD. ***$p < 0.0001$; **$p < 0.01$ versus measurement I

Ferulic acid is a well-known compound in the pharmaceutical, food, and cosmetic industries. It is widely used as a preservative,[20] photoprotective agent,[21] and vitamin stabilizer.[22] Its strong antioxidant activity is related to free radical scavenging,[18] inhibiting enzymes that catalyze free radical generation,[23] binding transition metals,[5] preventing lipid peroxidation, enhancing other scavenger enzymes activity.[24,25]

Ferulic acid shows an antioxidant activity due to the phenolic ring and unsaturated side chain.[12] It has the capacity to inhibit a complex

TABLE 1 Visioscan parameters values: exfoliation (SEsc) and roughness of the epidermis (SEr)

Parameter	Measurement 1	Measurement 2	Significance
Forehead			
SEr	2.98 ± 1.06	2.39 ± 0.82	$p = 0.151$
SEsc	0.45 ± 0.10	0.35 ± 0.07	$p = 0.031$*
Cheek			
SEr	3.87 ± 0.66	2.52 ± 0.18	$p = 0.103$
SEsc	0.54 ± 0.13	0.42 ± 0.06	$p = 0.115$
Jaw			
SEr	3.42 ± 0.82	2.35 ± 0.54	$p = 0.027$*
SEsc	0.49 ± 0.05	0.40 ± 0.11	$p = 0.175$

Note: Data presented as mean ± SD. Values of both parameters (Sesc and Ser) increase with age.
*$p < 0.05$.

TABLE 2 Control point[4] parameter's values according to the time of measurement

Parameter	Measurement 1	Measurement 2	Significance
Melanin	162.3 ± 42.6	159.8 ± 44.7	$p = 0.271$
Erythema	350.1 ± 64.6	349.6 ± 62.1	$p = 0.368$
Corneometer	55.9 ± 13.5	53.2 ± 11.1	$p = 0.162$
PK Vser	1.14 ± 0.19	1.14 ± 0.21	$p = 0.739$
PK Vsesc	0.57 ± 0.12	0.59 ± 0.11	$p = 0.383$

Note: Data presented as mean ± SD.

reaction of free radicals generation, by forming stable phenoxyl radicals, in the reaction of the radical molecule with the molecule of antioxidant. The phenoxy radical is formed, which is highly resonance stabilized, so it ends its life in condensation and collision with another ferulate radical. It has also the ability to donate atoms directly to the radicals, acting as a hydrogen donor. Another antioxidant mechanism, associated with binding transition metals such as iron and copper, prevents the formation of toxic hydroxyl radicals and in the aftermath autoxidation of lipid acids cell membrane.[5,12,26] Ferulic acid has the ability to inhibit enzymes that catalyze the formation of free radicals and of strengthening scavenger radical enzymes.[12]

Milani et al.[27] showed skin protective effects of an antioxidant and antipollution serum with *Deschampsia antartica* extract, ferulic acid, and vitamin C. The study was conducted on a group of 20 women living in an area of high pollution urban area. The study showed improvement of skin barrier function, to counteract the skin oxidative stress and to reduce hiperpigmentations.

In our research, nanosomal formulations were used (nanosome technology). Gupta et al.[28] states that ferulic acid has problems of poor stability and low aqueous solubility in cosmetics products. The solution obtained in the research was suggested to be an optimal concentration (0.5 wt% ferulic acid in bulk solution) for successful nanoemulsion formulation. In the study formulations of ferulic acid-loaded lipid-based nanoparticle systems, can find various uses in cosmetics.

FIGURE 5 Lightening activity of ferulic acid. I photograph—before, II photograph—after the treatment session. Women age 48. II type according to Glogau Wrinkle Scale. The level of melanin at the baseline: 175. The level of melanin after the eight treatments of FA peel: 133

FIGURE 6 The cutaneous superficial network of blood vessels. I photograph—before, II photograph—after the treatment session. The photograph taken by VISIA® Canfield Scientific showing the number and size of vascular lesions. Made in cross polarity in RBX® technology. Women age 58. II type according to Glogau Wrinkle Scale. The level of erythema at the baseline: 470. The level of erythema after the 8 treatment of FA peel: 385

Das and Wong researched to stabilize ferulic acid in topical hydrogel formulation via nanoencapsulation technique and low pH (less than pKa of ferulic acid). They proved that products with ferulic acid with low pH can maintain skin microbiome and homeostasis, may penetrate into skin layers (avoid systemic circulation).[29]

Further pre-treatment studies confirmed the great photoprotective ability of ferulic acid-loaded multiple emulsions (MA), in fact, following a 5 h pre-treatment with ME (W/O/W multiple emulsions), the skin of the volunteers become more protected from a subsequent physical insult and the erythema index remained on lower values than those of the sites pre-treated with the other formulations.[12]

As a result of excessive free radical reactions, the functioning of the skin is disturbed and aging is accelerated. Skin becomes dehydrated, sagging, wrinkled, appears discoloration and vascular spider veins. Treatment with ferulic acid counteracts photoaging of the skin, and also shows depigmenting properties, controlling tyrosinase activity. Because FA has a similar structure to tyrosine, it is believed that it inhibits melanogenesis through competitive inhibition with tyrosine. What else, vitamin E ferulic acid ester exhibited an inhibitory effect on melanin production.[30]

In this research series of treatments with ferulic acid peel, caused a decrease of skin melanin content and thus brightening and evening



FIGURE 7 Skin surface in a multiple magnification. I photograph—before, II photograph—after the treatment session. The photograph taken by Visioscan® VC98 showing the skin topography using a special UV-A light video camera with high resolution. The images show the structure of the skin and the level of dryness. Accurate analysis of the skin is made with the use of SELS® parameters (Surface Evaluation of the Living Skin)

of skin color. Minor hyperpigmentation has also been lightened and much less visible (Figure 5). Park et al. investigated the mechanism of the skin-whitening action of ferulic acid. It is based on the inhibition of intracellular tyrosinase synthesis in melanocytes. The synthesis of melanin is suppressed by reducing the expression of microphthalmia transcription factor (MITF)—a major transcriptional regulator of the genes for tyrosinase. Ferulic acid affects the synthesis and decomposition of the melanogenic enzyme, by controlling the activity of its transcription factor. Park et al.[31] in their study on B16F10 mouse melanoma cells showed a 19.1% decrease in intracellular tyrosine synthesis, after exposure to 20 μg/ml ferulic acid. The intensity of the melanin synthesis process decreased by 43.6%. Dayal et al.[32] in their study comparing the efficacy of 12% ferulic acid peel with two other common peels, noted good to excellent improvement (according to physician global assessment) in the intensity of periorbital hyperpigmentation (POH) in almost half of the FA group. What is more, 12% ferulic acid was the best-tolerated peel among the three.

Importantly, the effects achieved during a series of ferulic acid treatments persist over time. A month after the end of the series of treatments, the amount of melanin in the skin increased slightly, still showing a significant improvement, compared to the baseline. This may be related to the preventive role of ferulic acid, against changes in the skin caused by UVA and UVB radiation. Pluemsamran et al.[13] proved that there are much smaller photodamages in keratinocytes if ferulic acid is administered prior to UV radiation. Reactive oxygen species' production decreases significantly, endogenous antioxidants, that is, glutathione, and catalase undergo a smaller reduction, and their level returns to the state before exposure. Upon absorption of UV, phenol acids catalyze the stable phenoxy radical formation, ferulic acid terminating free radical chain reactions. Therefore, it can be assumed that ferulic acid not only reduces already existing signs of photoaging but also prevent future photodamage in the skin.[12]

Murray et al.[33] have demonstrated that a stable topical formulation of 15% L-ascorbic acid, 1% alphatocopherol, and 0.5% ferulic acid (CEFer) is able to significantly decrease the expression of immunosuppressive and proinflammatory cytokines that occurs with UV damage. CEFer was applied to separate patches of human skin for 4 days and next the skin was irradiated UV.

Mancuso et al.[12] conducted in vivo and in vitro research which the aim was the evaluation of three types of emulsions with ferulic acid. MA showed the best ability to carry and release ferulic acid and great stability. What is important, in vivo investigation showed that MA has the best capability to treat UV-B-induced erythema.

The study demonstrated that therapy with ferulic acid peel reduced the severity of erythema and visibility of telangiectasia. The best results were achieved on the forehead and cheeks, which is confirmed by the photo taken with the VISIA®, illustrating the cutaneous superficial network of blood vessels (Figure 6). Literature data indicate that ferulic acid has been used for a long time in neurodegenerative and circulatory system diseases. It also improves blood circulation, prevents thrombocyte clumping, and has antithrombotic properties.[34] Lin et al.[35] in their research on human umbilical vein endothelial cells (HUVEC), demonstrated that ferulic acid induces the expression of major angiogenic regulatory factors: vascular endothelial growth factor (VEGF) and platelet-derived growth factor (PDGF). It also increases the amount of hypoxia-inducible factor 1 (HIF-1)—a factor that generates a response to hypoxia. Treatment with ferulic acid leads to significant induction of VEGF, PDGF, and HIF-1α mRNA and protein expression, in a concentration-dependent and time-dependent manner. Due to the angiogenic effect, ferulic acid is supposed to be a new therapeutic agent for microcirculation disorders, also within the skin.

Ferulic acid also significantly increases skin hydration. The increase in hydration of the stratum corneum results in its smoothing, which was confirmed by the photos taken with Visioscan (Figure 7). Chiu et al.[36] demonstrated that topically applied antioxidants reduce transepidermal water loss, support the hydro-lipid barrier, contributing to the increase of water content in the epidermis. What is more, with several applications, they have the ability to cumulate in the epidermis and dermis. In order to achieve optimal results, antioxidant compounds should be used relatively frequently and regularly, which confirms the legitimacy of performing treatments with ferulic acid in the series. Kanlayavattanakul et al.[37] noted satisfactory effects in the form of improved hydration of the epidermis, after using a rice extract-rich in phenolic compounds, including ferulic acid. After 2 months of using the cream with rice extract, the level of hydration of the epidermis increased almost 2-times.

5 | CONCLUSIONS

The topical administration of ferulic acid could ensure activity against UV-induced photodamage.

An objective examination with the use of MPA probes—Mexameter and Corneometer, showed a significant whitening, moisturizing and erythema-reducing effect. The results achieved with apparatus, are reflected in photographic documentation. Within the limits of our study, we found the series of ferulic acid peel treatments, which seems to bring promising effects on photoaging skin. Nevertheless, these initial results need to be further validated on a larger sample size.

AUTHOR CONTRIBUTIONS

Zduńska-Pęciak Kamila is responsible for the study design, collecting the results, statistical analysis, preparing the preliminary version of the manuscript. Dębowska Renata contributed to the collection of results and photodocumentation. Anna Kołodziejczak checked and edited the article in terms of content. Rotsztejn Helena has made an assessment of the overall study design and the correctness of the draft of the manuscript.

ACKNOWLEDGMENTS

This work was supported by statutory research activity of the Department of Cosmetology and Aesthetic Dermatology, Faculty of Pharmacy, Medical University of Lodz, No. 503/3-066-01/503-31-001 and Grant/Award number 502-03/3-066-01/502-34-102.

FUNDING INFORMATION

Statutory research activity of the Department of Cosmetology and Aesthetic Dermatology, Faculty of Pharmacy, Medical University of Lodz, No. 503/3-066-01/503-31-001. Medical University of Łódź, Grant/Award Number: 502-03/3-066-01/502-34-102.

CONFLICT OF INTEREST

The authors have no conflicts of interest to declare.

DATA AVAILABILITY STATEMENT

The data that support the findings of this study are available from the corresponding author upon reasonable request.

ETHICS STATEMENT

All participants have given their written informed consent to the procedure. The study protocol has been approved by the Bioethics Committee of the Medical University of Lodz (Protocol No. RNN/81/19/KE). All procedures involving human probands were in accordance with the ethical standards of the institutional and/or national research committee and with the 1964 Helsinki declaration and its later amendments or comparable ethical standards.

ORCID

Kamila Zduńska-Pęciak https://orcid.org/0000-0002-3012-9054
Anna Kołodziejczak https://orcid.org/0000-0002-7799-9188

REFERENCES

1. Kawaguchi Y, Tanaka H, Okada T, et al. Effect of reactive oxygen species on the elastin mRNA expression in cultured human dermal fibroblasts. *Free Radi Biol Med*. 1997;23:162-165.
2. Augustyniak A, Rotsztejn H, Bartnicka E. Effects of reactive oxygen species on skin photoaging. *Dermatol Rev*. 2016;103:233-239.
3. Mattila P, Kumpulainen J. Determination of free and total phenolic acids in plant-derived foods by HPLC with diode-array detection. *J Agric Food Chem*. 2002;50:3660-3667.
4. Kim JK, Park SU. A recent overview on the biological and pharmacological activities of ferulic acid. *EXCLI J*. 2019;18:132-138.
5. Kiewlicz J, Szymusiak H, Zieliński R. Thermal stability and antioxidant activity of long-chain alkyl esters od ferulic acid. *Zywn Nauk Technol*. 2015;4:188-200.
6. Barone E, Calabrese V, Mancuso C. Ferulic acid and its therapeutic potential as a hormetin for age-related diseases. *Biogerontology*. 2009;10:97-108.
7. Alias LM, Manoharan S, Vellaichamy L, Balakrishnan S, Ramachandran CR. Protective effect of ferulic acid on 7,12-dimethylbenz[a] anthracene-induced skin carcinogenesis in swiss albino mice. *Exp Toxicol Pathol*. 2009;61:205-214.
8. Yasmin S, Cerchia C, Badavath VN, et al. A series of ferulic acid amides reveals unexpected peroxiredoxin 1 inhibitory activity with in vivo antidiabetic and hypolipidemic effects. *Chem Med Chem*. 2021;16:484-498.
9. Fathima S, Shona S, Navamimrajan N, et al. Development and evaluation of ferulic acid loaded chitosan gel for wound healing. *Int J Pharm Res*. 2021;13:2836-2843.
10. Draelos ZD, Yatskayer M, Oresajo C, Fares HS, Hansenne I. Efficacy of ferulic acid in improving the appearance of photoaged skin. *Cosmetic Dermatol*. 2008;21(4):195-198.
11. Lin F-H, Lin J-Y, Ravindra D, et al. Ferulic acid stabilizes a solution of vitamins C and E and doubles its photoprotection of skin. *J Invest Dermatol*. 2005;125:826-832.
12. Mancuso A, Cristiano MC, Pandolfo R, Greco M, Fresta M, Paolino D. Improvement of ferulic acid antioxidant activity by multiple emulsions: in vitro and in vivo. *Eval Nanomater*. 2021;11(2):425.
13. Pluemsamran T, Onkoksoong T, Panich U. Caffeic acid and ferulic acid inhibit UVA-induced matrix metalloproteinase-1 through regulation of antioxidant defense system in keratinocyte HaCaT cells. *Photochem Photobiol*. 2012;88:961-968.
14. Zhou B, Yin H, Xu Y, et al. Baicalin protects human skin fibroblasts from ultraviolet a radiation-induced oxidative damage and apoptosis. *Free Radic Res*. 2012;46:1458-1471.
15. Hahn H, Kim K, Bae S, et al. Pretreatment of ferulic acid protects human dermal fibroblasts against ultraviolet a irradiation. *Ann Dermatol*. 2016;286:740-748.
16. Oresajo C, Stephens T, Hino P, et al. Protective effects of a topical antioxidant mixture containing vitamin C, ferulic acid, and phloretin against ultraviolet-induced photodamage in human skin. *J Cosmet Dermatol*. 2008;74:290-297.
17. Bezerra G, Pereira M, Ostrosky E, et al. Compatibility study between ferulic acid and excipients used in cosmetic formulations by TG/DTG, DSC and FTIR. *J Therm Anal Calor*. 2017;127:1683-1691.
18. Saija A, Tomaino A, Lo Cascio R, et al. Ferulic and caffeic acids as potential protective agents against photooxidative skin damage. *J Sci Food Agric*. 1999;79:476-480.
19. Mathew S, Abraham ET. Ferulic acid: an antioxidant found naturally in plant cell walls and feruloyl esterases involved in its release and their applications. *Crit Rev Biotechnol*. 2004;24:59-83.
20. Yuan L, Haixia Y, Yong C, et al. Ferulic acid-β-cyclodextrin inclusion complexes: application on the preservation of hairtail (*Trichiurus lepturus*). *Int J Food Prop*. 2020;23:282-296.

21. Peres DD, Sarruf FD, de Oliveira CA, MVR V, Baby AR. Ferulic acid photoprotective properties in association with UV filters: multifunctional sunscreen with improved SPF and UVA-PF. *J Photochem Photobiol B*. 2018;185:46-49.
22. Romana-Souza B, Silva-Xavier W, Monte-Alto-Costa A. Topical application of a commercially available formulation of vitamin C stabilized by vitamin E and ferulic acid reduces tissue viability and protein synthesis in ex vivo human normal skin. *J Cosmet Dermatol*. 2020;19: 2965-2973.
23. Nile SH, Ko EY, Kim DH, Keum YS. Screening of ferulic acid related compounds as inhibitors of xanthine oxidase and cyclooxygenase-2 with anti-inflammatory activity. *Rev Bras Farmacogn*. 2016;26:50-55.
24. Lodovici M, Guglielmi F, Meoni M, Dolara P. Effect of natural phenolic acids on DNA oxidationin vitro. *Food Chem Toxicol*. 2001;39:1205-1210.
25. Masella R, Vari R, d'Archivio M, et al. Extra virgin olive oil biophenolsinhibit cell-mediated oxidation of LDL by increasing the mRNA transcription of glutathione-related enzymes. *J Nutr*. 2004; 134:785-791.
26. Scharffetter-Kochanek K, Brenneisen P, Wenk J, et al. Photoaging of the skin from phenotype to mechanisms. *Exp Gerontol*. 2000;35:307-316.
27. Milani M, Hashtroody B, Piacentini M, Celleno L. Skin protective effects of an antipollution, antioxidant serum containing *Deschampsia antartica* extract, ferulic acid and vitamin C: a controlled single-blind, prospective trial in women living in urbanized, high air pollution area. *Clin Cosmet Investig Dermatol*. 2019;29(12):393-399.
28. Gupta KM, Das S, Shan Chow P, Macbeath C. Encapsulation of ferulic acid in lipid nanoparticles as antioxidant for skin: mechanistic understanding through experiment and molecular simulation. *Nano Mater*. 2020;3(6):5351-5361.
29. Das S, Wong ABH. Stabilization of ferulic acid in topical gel formulation via nanoencapsulation and pH optimization. *Sci Rep*. 2020;10(1): 12288. doi:10.1038/s41598-020-68732-6
30. Kumar N, Pruthi V. Potential applications of ferulic acid from natural sources. *Biotechnol Rep*. 2014;16:86-93.
31. Park HJ, Cho JH, Hong SH, et al. Whitening and anti-wrinkle activities of ferulic acid isolated from *Tetragonia tetragonioides* in B16F10 melanoma and CCD-986sk fibroblast cells. *J Nat Med*. 2018;72:127-135.
32. Dayal S, Sangal B, Sahu P. Ferulic acid 12% peel: an innovative peel for constitutional type of periorbital melanosis—comparing clinical efficacy and safety with 20% glycolic peel and 15% lactic peel. *J Cosmet Dermatol*. 2020;19:2342-2348.
33. Murray JC, Burch JA, Streilein RD, Iannacchione MA, Hall RP, Pinnell SR. A topical antioxidant solution containing vitamins C and E stabilized by ferulic acid provides protection for human skin against damage caused by ultraviolet irradiation. *J Am Acad Dermatol*. 2008; 59(3):418-425.
34. Yogeeta SK, Hanumantra RB, Gnanapragasam A, et al. Attenuation of abnormalities in the lipid metabolism during experimental myocardial infarction induced by isoproterenol in rats: beneficial effect of ferulic acid and ascorbic acid. *Basic Clin Pharmacol Toxicol*. 2006;985: 467-472.
35. Lin CM, Chiu JH, Wu IH, Wang BW, Pan CM, Chen YH. Ferulic acid augments angiogenesis via VEGF, PDGF and HIF-1 alpha. *J Nutr Biochem*. 2010;217:627-663.
36. Chiu A, Kimball AB. Topical vitamins, minerals and botanical ingredients as modulators of environmental and chronological skin damage. *Br J Dermatol*. 2003;149:681-691.
37. Kanlayavattanakul M, Lourith N, Chaikul P. Jasmine rice panicle: a safe and efficient natural ingredient for skin aging treatments. *J Ethnopharmacol*. 2016;193:607-616.

How to cite this article: Zduńska-Pęciak K, Dębowska R, Kołodziejczak A, Rotsztejn H. Ferulic acid – A novel topical agent in reducing signs of photoaging. *Dermatologic Therapy*. 2022;e15543. doi:10.1111/dth.15543

2.4 Dyskusja

Wpływ kwasu ferulowego na wybrane parametry skóry: nawilżenie, poziom melaniny, nasilenie rumienia, elastyczność i topografię, został oceniony na podstawie wyników pomiarów uzyskanych za pomocą sond urządzenia MPA - The Multi Probe Adapter Systems (Courage + Khazaka electronic GmbH, Köln, Germany) oraz kamery Visioscan® VC 98. Ocena aparaturowa umożliwia dokonanie obiektywnej analizy zmian zachodzących pod wpływem zabiegów kosmetologicznych oraz będących wynikiem stosowania preparatów kosmetycznych. Sonda korneometryczna (Corneometer) jest jednym z najczęściej wybieranych urządzeń do oceny nawilżenia skóry. Została wykorzystana m.in. w wieloośrodkowym badaniu obejmującym liczną grupę 349 probantów, do oceny zmian nawilżenia różnych rodzajów skóry (bardzo suchej, suchej i normalnej) po aplikacji 3 typów emulsji [97]. Sonda meksametryczna (Mexameter) stanowiła z kolei główne urządzenie pomiarowe w badaniu zaburzeń pigmentacyjnych (hipopigmentacji), okazując się pomocną również w diagnozowaniu zmian skórnych [96]. Sonda kutometryczna (Cutometer) została wykorzystana m.in. do analizy i oceny mechanicznych parametrów, najlepiej reprezentujących wpływ starzenia się skóry (ang. age-related changes), w badaniu z udziałem 120 probantów [100]. Zmiany w ukształtowaniu powierzchni skóry, stopnia złuszczania i zrogowacenia naskórka były oceniane przy pomocy kamery Visioscan, po aplikacji preparatu zawierającego bogaty w antyoksydanty ekstrakt z nasion *Tamarindus indica* [101]. Inni badacze wykorzystali Visioscan do oceny stanu skóry po doustnej suplementacji preparatów zawierających mikroelementy [102]. Szerokie zastosowanie sond urządzenia MPA, w świetle obecnej literatury, tłumaczy zasadność zastosowania tego typu oceny aparaturowej w niniejszej pracy.

Badania własne wykazały istotne statystycznie zmiany w obrębie wszystkich badanych parametrów. Peeling chemiczny na bazie kwasu ferulowego okazał się skuteczną substancją zwiększającą elastyczność, zmniejszającą stopień nasilenia rumienia, rozjaśniającą przebarwienia, zwiększającą nawilżenie i wygładzającą powierzchnię skóry, co pozwala zakwalifikować FA do substancji niwelujących oznaki fotostarzenia skóry. Fotoprotekcyjne działanie kwasu ferulowego zostało wykazane już ponad 2 dekady temu, w badaniach nad oksydacyjnymi uszkodzeniami skóry pod wpływem promieniowania UV. Wyniki eksperymentu nad przeciwutleniającymi możliwościami FA, pozwoliły przypisać mu właściwości zapobiegające

fotouszkodzeniom skóry [103]. Dzięki temu jest także powszechnie stosowany w środkach ochrony przeciwsłonecznej, gdzie przedłuża działanie i zwiększa spektrum ochrony innych popularnie stosowanych filtrów UV [64, 104].

Połączenie działania kwasu ferulowego z mikronakłuwaniem dało znacząco lepsze efekty, w porównaniu do kwasu ferulowego aplikowanego samodzielnie. Chauhan i wsp. również zaobserwowali lepsze efekty w niwelowaniu objawów fotostarzenia się skóry w przypadku terapii łączonej, obejmującej 12% kwas ferulowy i 30% kwas mlekowy, w porównaniu do samego peelingu kwasem ferulowym. Według skali oceny zaawansowania starzenia (ang. Allergan Fine Line Scale - AFLS) odnotowano poprawę wyższą o 42%, porównując do poprawy po monoterapii [105]. Przewagę terapii łączonych wykazał także El-Domyati i wsp. w badaniach typu split-face, porównując skuteczność mikronakłuwania, wykonywanego samodzielnie oraz w połączeniu z osoczem bogatopłytkowym i 15% kwasem trójchlorooctowym (TCA) u probantów z objawami fotostarzenia skóry. Zarówno w ocenie klinicznej jak i w badaniu histopatologicznym odnotowano znacznie lepsze efekty przeciwstarzeniowe po zabiegach łączonych [106].

Kwas ferulowy stanowi składnik preparatów kosmetycznych stosowanych zarówno w użytku domowym, jak i gabinetach kosmetyki profesjonalnej. W literaturze dostępnych jest wiele publikacji, potwierdzających jego skuteczność, co tłumaczy powszechność zastosowania. Wnikliwy przegląd dostępnych artykułów pozwolił jednak zauważyć niewielką ilość badań nad kwasem ferulowym z udziałem probantów. Znacząca większość prac opiera się o analizę hodowli komórkowych oraz typowo chemiczne właściwości związku. W badaniach własnych postanowiono porównać kwas ferulowy z innym, dobrze przebadanym, powszechnie stosowanym antyoksydantem w terapii fotostarzenia - kwasem askorbinowym [107]. Porównanie oceny skuteczności kwasu ferulowego i kwasu askorbinowego nie wykazało znaczących różnic pomiędzy związkami. Oba zastosowane preparaty dały istotną statystycznie poprawę we wszystkich badanych parametrach skóry. Można zatem przypuszczać, że preparaty z kwasem ferulowym stanowić będą dobrą alternatywę dla tych z witaminą C. Jest to istotne przez wzgląd na nietrwałość różnych odmian kwasu askorbinowego oraz problemy ze skutecznym umieszczeniem ich w preparatach kosmetycznych [108]. Girsang i wsp. również porównał kwas ferulowy z inną substancją antyoksydacyjną

- kwasem protokatechowym w kontekście starzenia się skóry, poprzez zbadanie ich zdolności do inhibicji tyrozynazy, kolagenazy, elastazy i hialuronidazy. Uzyskane wyniki były dość zbliżone, z wyjątkiem większej skuteczności kwasu ferulowego w hamowaniu aktywności kolagenazy i przewagą kwasu protokatechowego w skuteczności inhibicji tyrozynazy [110].

Zarówno kwas ferulowy jak i kwas askorbinowy są rekomendowane do skóry fotostarzejącej się, szczególnie z obecnością przebarwień. Jaros i wsp. wykazali, że już 5% stężenie wit C w preparatach kosmetycznych zapewnia wysoką redukcję hiperpigmentacji oraz nasilenia rumienia [109]. W badaniach własnych również odnotowano wyraźną poprawę w ocenie meksametrycznej. Dayal i wsp. porównali skuteczność 20% kwasu glikolowego, 15% kwasu mlekowego i 12% kwasu ferulowego w niwelowaniu przebarwień okołooczodołowych (ang. periorbital hyperpigmentation - POH). Wszystkie kwasy oceniono na efektywne w zakresie rozjaśniania przebarwień (z największą przewagą kwasu glikolowego), jednak kwas ferulowy okazał się mieć najmniejsze działanie drażniące [111].

2.5 Wnioski

Z przeprowadzonych badań wynikają następujące wnioski:

1) Seria zabiegów z użyciem peelingu chemicznego na bazie kwasu ferulowego istotnie wpływa na poprawę nawilżenia, rozjaśnienie przebarwień, niwelację rumienia, wygładzenie powierzchni i wzrost elastyczności skóry. Uzyskana poprawa utrzymuje się w czasie - po miesiącu od zakończenia serii zabiegów wyniki pozostały istotnie wyższe od pomiarów wyjściowych.

2) Zabieg obejmujący połączenie kwasu ferulowego z mikronakłuwaniem daje lepsze efekty, niż zastosowanie peelingu ferulowego samodzielnie.

3) Nie wykazano istotnych statystycznie różnic dotyczących skuteczności kwasu ferulowego i kwasu askorbinowego w niwelowaniu objawów fotostarzenia skóry - oba związki wykazały znaczącą poprawę we wszystkich badanych parametrach.

4) Dokumentacja fotograficzna potwierdziła uzyskane w ocenie aparaturowej wyniki - u wszystkich probantek widać znaczną poprawę stanu skóry po serii zabiegów z użyciem kwasu ferulowego.

3 STRESZCZENIE

Kwas ferulowy jest silnym antyoksydantem pochodzenia roślinnego, do niedawna stosowanym synergistycznie z innymi przeciwutleniaczami, takimi jak: witamina C, witamina E, zwiększając ich działanie i uczestnicząc w regeneracji. Formuły wzbogacone o kwas ferulowy zyskują kilkukrotnie wyższą skuteczność antyoksydacyjną oraz fotoprotekcyjną. W pracy postanowiono ocenić wpływ kwasu ferulowego w formie peelingu chemicznego na wybrane parametry skóry twarzy: nawilżenie, poziom melaniny, nasilenie rumienia, topografię, elastyczność skóry. Obiektywna ocena skuteczności zabiegów kosmetologicznych, stanowi istotne źródło wiedzy na temat stosowanych metod. W celu zoptymalizowania możliwych do osiągnięcia efektów postanowiono porównać aplikację samego kwasu ferulowego, z zabiegiem łączonym obejmującym mikronakłuwanie poprzedzone aplikacją peelingu z kwasem ferulowym. Dokonano także porównania skuteczności z inną powszechnie stosowaną substancją antyoksydacyjną - kwasem askorbinowym. W świetle obecnej wiedzy wiadomo, że kwas ferulowy wywiera korzystny wpływ na hodowle komórkowe fibroblastów, keratynocytów, melanocytów, chroniąc je przed niekorzystnym wpływem promieniowania UV, głównie dzięki właściwościom antyoksydacyjnym. Dostępnych jest jednak niewiele danych literaturowych oceniających wpływ kwasu ferulowego na skórę probantów.

Badaniem objęto 56 probantek, o średniej wieku 54,2 lat (zakres 39-61 lat) z widocznymi objawami fotostarzenia się skóry, które podzielono na 3 grupy badane. U wszystkich wykonano serię 8 zabiegów w 1-tygodniowych odstępach czasu. 20 probantek poddano zabiegom aplikacji samego peelingu ferulowego, u 16 probantek wykonano zabieg typu split-face aplikując na jedną połowę twarzy sam peeling ferulowy, na drugą- w połączeniu z mikronakłuwaniem skóry, u 20 pozostałych - zabieg typu split-face aplikując na jedną połowę twarzy peeling ferulowy, na drugą - serum z kwasem askorbinowym. Oceny skuteczności zabiegów dokonano za pomocą sond Mexameter, Korneometer, Cutometer urządzenia MPA - The Multi Probe Adapter Systems (Courage + Khazaka electronic GmbH, Köln, Germany) oraz kamerą Visioscan® VC 98. Przed przystąpieniem do badania oraz po zakończeniu serii zabiegów, wykonano zdjęcia systemem fotograficznym VISIA® Complexion Analysis System (Canfield Scientific, Inc.) oraz Fotomedicus (Elfo®).

Cele pracy:

1) Ocena aparaturowa wpływu kwasu ferulowego na: nawilżenie, poziom melaniny, nasilenie rumienia, topografię, elastyczność skóry.
2) Ocena porównawcza wpływu kwasu ferulowego oraz kwasu ferulowego z mikronakłuwaniem na wybrane parametry skóry: nawilżenie, poziom melaniny, nasilenie rumienia, topografię, elastyczność.
3) Ocena porównawcza wpływu kwasu ferulowego oraz witaminy C na wybrane parametry skóry: nawilżenie, poziom melaniny, nasilenie rumienia, topografię, elastyczność.
4) Ocena skuteczności zastosowanych zabiegów na podstawie dokumentacji fotograficznej.

Z przeprowadzonych badań wynikają następujące wnioski:

1) Seria zabiegów z użyciem peelingu chemicznego na bazie kwasu ferulowego istotnie wpływa na poprawę nawilżenia, rozjaśnienie przebarwień, niwelację rumienia, wygładzenie powierzchni i wzrost elastyczności skóry. Uzyskana poprawa utrzymuje się w czasie - po miesiącu od zakończenia serii zabiegów wyniki pozostały istotnie wyższe od pomiarów wyjściowych.

2) Zabieg obejmujący połączenie kwasu ferulowego z mikronakłuwaniem daje lepsze efekty, niż zastosowanie peelingu ferulowego samodzielnie.

3) Nie wykazano istotnych statystycznie różnic dotyczących skuteczności kwasu ferulowego i kwasu askorbinowego w niwelowaniu objawów fotostarzenia skóry - oba związki wykazały znaczącą poprawę we wszystkich badanych parametrach.

4) Dokumentacja fotograficzna potwierdziła uzyskane w ocenie aparaturowej wyniki - u wszystkich probantek widać znaczną poprawę stanu skóry po serii zabiegów z użyciem kwasu ferulowego.

4 STRESZCZENIE W JĘZYKU ANGIELSKIM

Summary

Ferulic acid is a strong antioxidant of plant origin until recently used synergistically with other antioxidants, i.e. vitamin C, vitamin E, increasing their activity and participating in regeneration. Formulas enriched with ferulic acid gain several times higher antioxidant and photoprotective effectiveness. In this study, we decided to evaluate the effect of ferulic acid in the form of a chemical peel on selected skin parameters: hydration, the level of melanin, erythema severity, skin topography and elasticity. Objective assessment of the effectiveness of cosmetological treatments is an important source of knowledge about the methods used. In order to optimize the possible effects, it was decided to compare the application of ferulic acid alone with a combined treatment involving microneedling preceded by the application of ferulic peeling. A comparison of effectiveness was also made with another commonly used, strong antioxidant - ascorbic acid. In the light of current knowledge, it is known that ferulic acid has a beneficial effect on cell cultures of fibroblasts, keratinocytes, and melanocytes, protecting them from the adverse effects of UV radiation, mainly due to antioxidant properties. However, there is little literature data assessing the effect of ferulic acid on the probants' skin.

The study included 56 probants, with an average age of 54.2 years (range 39-61 years) with visible signs of photoaging, which were divided into 3 groups. All of them underwent a series of 8 treatments at 1-week intervals. 20 probants (Group 1) received treatment sessions with the application of ferulic peeling alone, in 16 probants (Group 2) split-face treatments were performed, involving applying ferulic peeling independently to one half of the face, on the other half of the face - ferulic peeling in combination with microneedling, in 20 others (Group 3) - a split-face treatment applying ferulic peeling to one half of the face, on the other half of the face - a serum with ascorbic acid. The effectiveness of the treatments was assessed using: Mexameter, Korneometer, Cutometer - the probes of MPA - The Multi Probe Adapter Systems (Courage + Khazaka electronic GmbH, Köln, Germany) and the camera - Visioscan® VC 98. Before and after the series of treatments photographic

documentation was made with the use of VISIA® Complexion Analysis System (Canfield Scientific, Inc.) and Fotomedicus (Elfo®).

The purpose of this study involves:

1) The assessment of the effect of ferulic acid on skin hydration, melanin level, erythema severity, and skin topography and elasticity.

2) Comparative assessment of the influence of ferulic acid and ferulic acid with microneedling on selected skin parameters: hydration, melanin level, erythema severity, skin topography, elasticity.

3) Comparative assessment of the influence of ferulic acid and vitamin C on selected skin parameters: hydration, melanin level, erythema severity, skin topography, elasticity.

4) Evaluation of the effectiveness of the above treatments on the basis of photographic documentation.

The following conclusions are drawn from the study:

1) A series of treatments using a chemical peel based on ferulic acid significantly improves skin hydration, lightens hyperpigmentation, reduces erythema, smoothes the surface of the skin, and increases skin elasticity. The improvement persists over time – one month after the end of the series of treatments, the results were still significantly higher compared to the measurement before the therapy.

3) The treatment involving the combination of ferulic acid with microneedling gives better therapeutic effects than using ferulic peeling alone.

4) The effectiveness of ferulic acid and ascorbic acid in eliminating the symptoms of photoaging of the skin does not differ significantly. Both compounds showed a significant improvement in all tested parameters.

5) Photographic documentation confirmed the results obtained in the apparatus assessment – all probants show a significant improvement in the condition of the skin after a series of treatments using ferulic acid.

5 PIŚMIENNICTWO

1. Kris-Etherton PM, Hecker KD, Bonanome A. *Bioactive compounds in food: their role in the prevention of cardiovascular disease and cancer*. Am J Med 2002;113:71-88.
2. Yaar M, Gilchrest B.A. *Photoaging: mechanism, preventing and therapy*. Br J Dermatol 2007;157:874-887.
3. Makrantonaki E, Zouboulis C. *Molecular mechanisms of skin aging: state of the art.* N Y Acad Sci USA 2007;1119:40-50.
4. Seckmeyer G, Pissulla D, Glandorf M, Henriques D, Johnsen, Webb A. *Variability of UV irradiance in Europe*. Photochem Photobiol 2008;84:172-179.
5. Diffey B.L. *Sources and measurement of ultraviolet radiation*. Methods 2002;28:4-13.
6. Olek-Hrab K, Hawrylak A, Czarnecka-Operacz M. *Wybrane zagadnienia z zakresu starzenia się skóry*. Post Dermatol Alergol 2008;25:226-34.
7. Ata P, Majewski S. *Photoaging of human skin*. Dermatology Review 2013;100(3):178-183.
8. Rhodes L.E, Gledhill K, Masoodi M, Haylett A.K, Brownrigg M, Thody A.J. *The sunburn response in human skin is characterized by sequential eicosanoid profiles that may mediate its early and late phases*. FASEB J 2009;23:3947-3956.
9. Jiang S.J, Chen J.Y, Lu Z.F, Yao J, Che D.F, Zhou X.J. *Biophysical and morphological changes in the stratum corneum lipids induced by UVB irradiation*. J Dermatol Sci 2006;44:29-36.
10. Kieć-Świerczyńska M. *Alergiczne kontaktowe zapalenie skóry. Patomechanizm.* Alergia 2009;1:33-37.
11. Loser K.A., Mehling S., Leser J., Apelt A., Kuhn S., Grabbe T. *Epidermal RANKL controls regulatory T-cells numbers via activation of dendritic cells*. Nat Med. 2006;12:1372-1379.
12. Tran T, Schuman J, Fisher D.E. *UV and pigmentation: molecular mechanisms and social controversies.* Pigment Cell Melanoma Res 2008;21:509-516.
13. Miękoś-Zydek B, Czyż P. *Zaburzenia pigmentacji skóry – przebarwienia.* [w:] Adamski Z, Kaszuba A (red.). Dermatologia dla kosmetologów. Wydawnictwo

Naukowe Uniwersytetu Medycznego im. Karola Marcinkowskiego w Poznaniu, Poznań 2008:114-117.

14. Amano S. *Characterization and mechanisms of photoageing-related changes in skin. Damages of basement membrane and dermal structures.* Exp Dermatol. 2016;25:14-9.
15. Warren R, Garstein V, Kligman A.M, Montana W, Allendorf R.A, Ridder G.M. *Age, sunlight and facial skin: a histologic and quantitative study.* J Am Acad Dermatol 1991;25:751-760.
16. Hachiya A, Sriwiriyanont P, Fujimura T, Ohuchi A, Kitahara T, Takema Y. *Mechanistic effects of longterm ultrafiolet B irradiation induce epidermal and dermal changes in human skin xenografts.* Am J Pathol 2009;174:401-413.
17. Seite S, Zucchi H, Septier D, Igondjo-Tchen S, Senni K, Godeau G. *Elastin changes during chronological and photo- ageing: the important role of lysozyme.* JEADV 2006;20:980-987.
18. Miyachi Y, Ishikawa O. *Dermal connective tissue metabolism in photoageing.* Australas J Dermatol. 1998;39(1):19-23.
19. Rabe J.H, Mamelak A.J, McElqunn R.J, Morison W.L, Sauder D.N. *Photoaging: mechanisms and repairs.* J Am Acad Dermatol 2006;55:1-19.
20. Bernstein E, Underhill C, Hahn P, Brown D, Uitto J. *Chronic sun exposure alters both the content and distribution of dermal glycosaminoglycans.* Br J Dermatol. 1996;135(2):255-62
21. Mrózek-Ryszawa N, Kawczyńska-Dróżdż A, Biernacka B. *Roślinne polifenole-przeciwutleniacze na które czekamy?* Czynniki Ryzyka. 2008;2:73-87.
22. Divakaran, S.A, Anitha CT. *Estimation of ferulic acid from selected plant materials by Spectrophotometry and High performance liquid chromatography.* Journal of Applied and Natural Science. 2021;13(2);815 - 819.
23. Dutt S. *General synthesis of a-unsaturated acids from malonic acid.* Chem. Soc. 1925;1:297–301.
24. Budryn G, Nebesny E. *Fenolokwasy – ich właściwości, występowanie w surowcach roślinnych, wchłanianie i przemiany metaboliczne.* Bromatol. Chem. Toksykol. 2006;39:103-110.

25. Kazimierczak R, Hallmann E, Sokołowska O, Rembiałkowska E. *Zawartość związków bioaktywnych w roślinach.* Journal of Research and Applications in Agricultural Engineering. 2011;56:106-108.
26. Slavin J, Marquart L, Jakobs D. *Consumption of whole-grain food and decreased risk of cancer: proposed mechanisms.* Cereal Foods World. 2000;45(2):54-58.
27. Zhao Z, Moghadasian MH. *Chemistry, natural sources, dietary intake and pharmacokinetic properties of ferulic acid: a review*. Food Chem. 2008;109:691–702.
28. Rice-Evans CA, Miller NJ, Paganga G. *Structure-antioxidant activity relationships of flavonoids and phenolic acids.* Free Radic Biol Med. 1996;20(7):933-56.
29. Castellucio C, Paganga G, Melikan N, Bowell G.P, Pridham J, Sampson J, Rice-Evans C. *Antioxidant potential of intermediates in phenylopropanoid metabolism in higher plants.* FEBS Letter. 1995;368:188-192.
30. Kurek M. *Microbial transformation of vanillic acid.* Advancm of microbiol. 2014;1(53):25-3.
31. Wright J.S, Johnson E.R, DiLabio G.A. *Predicting the Activity of Phenolic Antioxidants: Theoretical Method, Analysis of Substituent Effects, and Application to Major Families of Antioxidants.* J Am Chem Soc. 2001;123(6):1173-1183.
32. Lucarini M, Pedulli G.F. *Free radical intermediates in the inhibition of the autoxidation reaction*. Chem. Soc. Rev. 2010;39:2106-2119.
33. Yin H, Xu L, Porter NA. *Free radical lipid peroxidation: mechanisms and analysis*. Chem Rev. 2011;12(10):5944-72.
34. Siquet C, Pavia-Martins F, Lima J. *Antioxidant profile of dihydroxy- and trihydroxyphenolic acids – a structure – acivity relationship study*. Free Radic Res 2006;40(4):433-42.
35. Amić A, Marković Z, Dimitrić Marković JM, Milenković D, Stepanić V. *Antioxidative potential of ferulic acid phenoxyl radical.* Phytochemistry. 2020;170:112218.

36. Galano A, Mazzone G, Alvarez-Diduk R, Marino T, Alvarez-Idaboy J.R, Russo N. *Food antioxidants: chemical insights at the molecular level.* Ann. Rev. Food Sci. Technol. 2016;7,335–352.
37. Amorati R, Attanasi O, Favi G, Menichetti S, Pedulli G, Viglianisi C. *Amphiphilic antioxidants from "cashew nut shell liquid" (CNSL) waste.* Org. Biomol. Chem. 2011;9:1352-1355.
38. Zhang HY, Ji HF. *How vitamin E scavenges DPPH radicals in polar protic media.* New J. Chem. 2006;30:503–504.
39. Kiewlicz J, Szymusiak H, Zieliński R. *Thermal stability and antioxidant activity of long-chain alkyl esters od ferulic acid.* Zywn Nauk Technol Ja. 2015;4:188–200.
40. Scharffetter-Kochanek K, Brenneisen P, Wenk J, Herrmann G, Ma W, Kuhr L. *Photoaging of the skin from phenotype to mechanisms*. Exp Gerontol. 2000;35:307–316.
41. Wong PY, Kitts DD. *An iron binding assay to measure activity of known food sequestering agents: studies with buttermilk solids.* Food Chem. 2001;72:245–254.
42. Kehrer JP. *The Haber–Weiss reaction and mechanisms of toxicity*. Toxicology. 2000;149:43–50.
43. Finefrock AE, Bush AI, Doraiswamy PM. *Current status of metals as therapeutic targets in Alzheimers disease*. J Am Ger Soc. 2003;51:1143–1148.
44. Sroka Z, Cisowski W. *Hydrogen peroxide scavenging, antioxidant and anti-radical activity of some phenolic acids.* Food Chemical Toxicology. 2003;41:753–758.
45. Halliwell B. *Antioxidant and human disease: a general introduction*. Nutr Rev 1997; 55:552-4.
46. Wang SW, Wang YJ, Su YJ, Zhou WW, Yang SG, Zhang R, Zhao M. *Rutin inhibits β-amyloid aggregation and cytotoxicity, attenuates oxidative stress and decreases the production of nitric oxide and proinflammatory cytokines.* Neurotoxicology. 2012;33:482-490
47. Ho DJ, Calingasan NY, Wille E, Dumont M, Beal MF. *Resveratrol protects against peripheral deficits in a mouse model of Huntington's disease.* Exp Neurol. 2010;225:74-84

48. Chung IM, Kim EH, Yeo MA. *Antidiabetic effects of three Korean sorghum phenolic extracts in norma and streptozotocin-induced diabetic rats.* Food Res Internat 2011; 44:127-32.
49. Jung EH, Kim SR, Hwang IK, Ha TY. *Hypoglycemic effects of a phenolic acid fraction of rice bran and ferulic acid in C57BL/KsJ-db/db mice*. J Agr Food Chem. 2007;55:9800-9804.
50. Jeszka M, Flaczek E, Kobus-Cisowska J. *Związki fenolowe – charakterystyka i znaczenie w technologii żywności.* Nauka Przyr Technol. 2010;4(2):1-13.
51. Tada H, Ikeda Y, Omoto T. *Rosmarinic acid and related phenolic in adventitius root cultures of Ociumum basilicum L.* Plant Tissue Cult Lett. 1996;13(1):69-71
52. Frankel EN, Kanner J, German JB. *Inhibition of oxidation of human lowdensity lipoprotein by phenolic substanses in red wine.* Lancet. 1993;341:454-457.
53. Fernández MA, García MD, Sáenz MT. *Antibacterial activity of the phenolic acids fraction of Scrophularia frutescens and Scrophularia sambucifolia.* J Ethnopharmacol 1996;53:11-4
54. Janicki A. *Żywność funkcjonalna – potrzeba żywieniowa czy promocja nowych wyrobów.* Bezp żyw. 2001;1:5-8.
55. Jędrusek-Golińska A, Hęś M. *Konsumenci a przeciwutleniacze w żywności*. Przem. Spoż. 2000;2:56:51.
56. Brand-Williams W, Cuvelier, Berset CM. *Use of free radical method to evaluate antioxidant activity*. Lebensm.-Wiss. U.-Technol. 1995;28:25-30
57. Zegarska Z, Amarowicz, Karamac M, Rafałowski R. *Antioxidative effect of rosemary ethanolic extract on butter*. Milchwissenschaft. 1996;51(4):195-198.
58. Mitek M, Gasik A. *Polifenole w żywności. Wpływ na cechy organoleptyczne*. Przem. Spoż. 2009;5:34-39.
59. Pluemsamran T, Onkoksoong T, Panich U. *Caffeic acid and ferulic acid inhibit UVA-induced matrix metalloproteinase-1 through regulation of antioxidant defense system in keratinocyte HaCaT cells.* Photochem Photobiol. 2012;88:961–968.
60. Hahn HJ, Kim KB, Bae S, Choi BG, An S, Ahn KJ, Kim SJ. *Pretreatment of ferulic acid protects human dermal fibroblasts against ultraviolet A irradiation.* Ann Dermatol. 2016;28:740–748.

61. Ambothi K, Nagarajan RP. *Ferulic acid prevents ultraviolet-B radiation induced oxidative DNA damage in human dermal fibroblasts*. Int J Nutr Pharmacol Neurol Dis. 2014;4:203–213.
62. Frątczak A, Bylka W, Studzińska-Sroka E. *Fenolokwasy – budowa, działanie i znaczenie w kosmetologii.* Pol J Cosmetol. 2015;18(4):270-274.
63. Czarnota A. *Chemoeksfolacja – substancje stosowane w peelingach medycznych oraz wskazania do ich stosowania*. Kosm Estet. 2017;6(2):147-152.
64. Oresajo C, Stephens T, Hino PD. *Protective effects of a topical antioxidant mixture containing vitamin C, ferulic acid, and phloretin against ultraviolet-induced photodamage in human skin.* J Cosmet Dermatol. 2008;7:290–297.
65. Shasha H, Yuhong G, Jingxia Z. *Ferulic acid protects against heat stress-induced intestinal epithelial barrier dysfunction in IEC-6 cells via the PI3K/Akt-mediated Nrf2/HO-1 signaling pathway.* Int J Hyperthermia. 2018;35:112-121.
66. Murray JC, Burch JA, Streilein RD, Iannacchione MA, Hall RP, Pinnell SR. *A topical antioxidant solution containing vitamins C and E stabilized by ferulic acid provides protection for human skin against damage caused by ultraviolet irradiation*. J Am Acad Dermatol. 2008;59:418–425.
67. Lin C, Chiu J, Wu I, Wang B. *Ferulic acid augments angiogenesis via VEGF, PDGF and HIF-1 alpha*. J Nutr Biochem. 2010;21:627-633.
68. Staniforth V, Huang W, Aravindaram K, Yang N. *Ferulic acid, a phenolic phytochemical, inhibits UVB-induced matrix metalloproteinases in mouse skin via posttranslational mechanisms.* J Nutr Biochem. 2012; 23:443-451.
69. Badran, M, Kuntsche, J, Fahr, *A. Skin penetration enhancement by a microneedle device (Dermaroller) in vitro: Dependency on needle size and applied formulation*. Eur J Pharm Sci. 2009;36:511–523
70. McCrudden MT, McAlister E, Courtenay AJ, González-Vázquez P, Singh TR, Donnelly RF. Microneedle applications in improving skin appearance. Exp Dermatol. 2015;24:561–566.
71. Aust MC, Fernandes D, Kolokythas P, Kaplan HM, Vogt PM. *Percutaneous collagen induction therapy: An alternative treatment for scars, wrinkles, and skin laxity*. Plast Reconstr Surg. 2008;121:1421–1429
72. Fernandes D. *Minimally invasive percutaneous collagen induction.* JOMFP. 2005;17:51–63

73. Šuca H, Zajícek R, Vodsloň Z. *Microneedling – A form of collagen induction therapy – Our first experiences.* Acta Chirurgiae Plasticae. 2017;59:33–36
74. Mina M, Elgarhy L, Al-Saeid H, Ibrahim Z. *Comparison between the efficacy of microneedling combined with 5-fluorouracil vs microneedling with tacrolimus in the treatment of vitiligo.* J Cosmet Dermatol. 2018;1473–2165.
75. Dhurat R, Sukesh M, Avhad G, Dandale A, Pal A, Pund PA. *Randomized evaluator blinded study of effect of microneedling in androgenetic alopecia: A pilot study*. Int J Trichology. 2013;5:6–11.
76. Arora S, Gupta P. *Automated microneedling device – A new tool in dermatologist's kit – A review.* JPAD. 2012;22:354–357.
77. Buganza A, Kuhl E. *Systems-based approaches toward wound healing*. Ped Res. 2013;73:553–563.
78. Koca KA, Cecen D, Gurgen SG, Sayin O, Cetin F. *A comparison study of growth factor expression following treatment with transcutaneous electrical nerve stimulation, saline solution, povidone-iodine, and lavender oil in wounds healing*. Evid based Complement Alternat Med. 2013;2013:361832
79. Greaves NS, Ashcroft KJ, Baguneid M, Bayat A. *Current understanding of molecular and cellular mechanisms in fibroplasia and angiogenesis during acute wound healing*. J Dermatol Sci. 2013;72:206–217.
80. McDougall S, Dallon J, Sherratt J, Maini P. *Fibroblast migration and collagen deposition during dermal wound healing: Mathematical modelling and clinical implications.* Philosophical Transactions. Series A, Mathematical, Physical, and Engineering Sciences. 2006;364:1385–1405.
81. Gabbiani G. *The myofibroblast in wound healing and fibrocontractive diseases*. J Pathol. 2003;200:500–503.
82. Nair PA, Arora TH. *Microneedling using dermaroller: A means of collagen induction therapy*. Gujarat Med J. 2014;69:24–27.
83. Laws RA, Finley EM, McCollough ML, Grabski WJ. *Alabaster skin after carbon dioxide laser resurfacing with histologic correlation.* Dermatol Surg. 2012;26:137–140.
84. Rawlins JM. *Quantifying collagen type in mature burn scars: A novel approach using histology and digital image analysis*. J Burn Care Res. 2006;27:60–65.

85. Fabrocini G, DeVita V, Pastore F. *Collagen induction therapy for the treatment of upper lip wrinkles.* J Dermatol Treat. 2012;23:144–152
86. Liebl H, Kloth LC. *Skin cell proliferation stimulated by microneedles*. J Am Coll Cert Wound Spec. 2012;4:2–6.
87. El-Domyati M, Barakat M, Awad S, Medhat W, El-Fakahany H, Farag H. *Microneedling therapy for atrophic acne scars an objective evaluation*. J Clin Aesthet Dermatol. 2015;8:36–42.
88. Dogra S, Yadav S, Sarangal R. *Microneedling for acne scars in Asian skin type: An effective low cost treatment modality*. J Cosm Dermatol. 2014;13:180–187.
89. El-Domyati M, Medhat W. *Minimally invasive facial rejuvenation: current concepts and future expectations.* Expert Rev Dermatol. 2013;8:565-580
90. Budamakuntla L, Loganathan E, Suresh DH, Shanmugam S, Suryanarayan S, Dongare A. *A randomised, open-label, comparative study of tranexamic acid microinjections and tranexamic acid with microneedling in patients with melasma*. J Cut Aesth Surg. 2013;6:139–143.
91. Sharad J. *Combination of microneedling and glycolic acid peels for the treatment of acne scars in dark skin*. J Cosm Dermatol. 2011;10:317–323.
92. Kim JH, Park HY, Jung M, Choi EH. *Automicroneedle therapy system combined with topical tretinoin shows better regenerative effects compared with each individual treatment.* Clin Exp Dermatol. 2012;38:57–65.
93. Lee HJ, Lee EG, Kang S, Sung JH, Chung HM, Kim DH. *Efficacy of microneedling plus human stem cell conditioned medium for skin rejuvenation: A randomized, controlled, blinded split face study.* Ann Dermatol. 2014;26,:584–591
94. Asif M, Kanodia S, Singh K. *Combined autologous platelet-rich plasma with microneedling verses microneedling with distilled water in the treatment of atrophic acne scars: A concurrent split-face study.* J Cosm Dermatol. 2016;15: 434–443
95. Chawla S. *Split face comparative study of microneedling with PRP versus microneedling with vitamin C in treating atrophic post acne scars.* JCAS. 2014;7:209–212.

96. Park ES, Na JI, Kim SO, Huh CH, Youn SW, Park KC. *Application of a pigment measuring device--Mexameter--for the differential diagnosis of vitiligo and nevus depigmentosus*. Skin Res Technol. 2006;12(4):298-302.
97. Heinrich U. *Multicentre comparison of skin hydration in terms of physical-, physiological- and product-dependent parameters by the capacitance method (Corneometer CM 825).* Int J Cosm Sci. 2003;25:45-51
98. Clarys Ron Clijsen P, Barel A. *Influence of probe application pressure on in vitro and in vivo capacitance (Corneometer CM 825) and conductance (Skicon 200 EX) measurements.* Skin Res Tech. 2011;17:445–450.
99. Akhtar N, Waqas MK, Ahmed M, Saeed T, Murtaza G, Rasool A, Aamir MN, Khan SA, Bhatti NS, Ali A. *Effect of Cream Formulation of Fenugreek Seed Extract on Some Mechanical Parameters of Human Skin*. Trop J Pharm Res. 2010;9(4):329-340.
100. Krueger N, Luebberding S, Oltmer M. *Age-related changes in skin mechanical properties: a quantitative evaluation of 120 female subjects.* Skin Res Tech. 2011;17:141-148.
101. Muhammad KW, Barkat AK, Naveed A, Farzana C, Haroon K, Sattar B, Shahzeb K, Akhtar R. *Fabrication of Tamarindus indica seeds extract loaded-cream for photo-aged skin: Visioscan® studies.* Adv Dermatol Allergol 2017;4:339–345.
102. Ferial F, Mac-Mary S, Jeudy A. *Efficacy of micronutrient supplementation on skin aging and seasonal variation: a randomized, placebo-controlled, double-blind study.* Clin Interv Aging. 2013;8:1527–1537.
103. Saija A, Tomaino A, Lo Cascio R, Trombetta D. *Ferulic and caffeic acids as potential protective agents against photooxidative skin damage*. J Sci Food Agric. 1999;79:476-480.
104. Peres DD, Sarruf FD, de Oliveira CA, Velasco MVR, Baby AR. *Ferulic acid photoprotective properties in association with UV filters: multifunctional sunscreen with improved SPF and UVA-PF.* J Photochem Photobiol B. 2018;185:46-49.
105. Chauhan A, Singh S. *Comparative Analysis of Efficacy of Lactic Acid with Ferulic Peel (Combination Peel) Vs Ferulic Peel Alone as a Monotherapy for Photoaging.* Aesthetic Plast Surg. 2021;45(1):281-288.

106. El-Domyati M, Abdel-Wahab H, Hossam A. *Combining microneedling with other minimally invasive procedures for facial rejuvenation: a split-face comparative study*. Int J Dermatol. 2018;57(11):1324-1334.
107. Humbert PG, Haftek M, Creidi P. *Topical ascorbic acid on photoaged skin. Clinical, topographical and ultrastructural evaluation: double-blind study vs. placebo*. Exp Dermatol. 2003;12:237-244.
108. Al-Niaimi F, Chiang NYZ. *Topical vitamin C and the skin: mechanisms of action and clinical applications. J Clin Aesthet Dermatol*. 2017;10:14-17.
109. Jaros A, Zasada M, Budzisz E, Dębowska R, Gębczynska-Rzepka M, Rotsztejn H. *Evaluation of selected skin parameters following the application of 5% vitamin C concentrate. J Cosmet Dermatol*. 2019;18:236-241.
110. Girsang E, Lister N, Ginting C, Bethasari M. *Comparison of Antiaging and Antioxidant Activities of Protocatechuic and Ferulic Acids*. MCBS. 2020;4:68-72.
111. Dayal S, Sangal B, Sahu P. *Ferulic acid 12% peel: An innovative peel for constitutional type of periorbital melanosis-Comparing clinical efficacy and safety with 20% glycolic peel and 15% lactic peel.* J Cosmet Dermatol. 2020;19(9):2342-2348.

6 SPIS RYCIN I TABEL

Ryc. 1. Wzór strukturalny kwasu ferulowego [23] 7
Ryc. 2. Szlak syntezy kwasów hydroksycynamonowych 9
Ryc. 3. Równanie reakcji powstawania rodnika fenoksylowego [amic a] 11
Ryc. 4. Punkty pomiarowe 29
Ryc. 5. Zasada pomiaru dokonywanego przez Meksametr 30
Ryc. 6. Zasada pomiaru dokonywanego przez Korneometr 31
Ryc. 7. Zasada pomiaru dokonywanego przez Kutometr 32
Ryc. 8. Krzywa deformacji skóry uzyskana za pomocą Kutometru [100] 32
Ryc. 9. Zasada pomiaru dokonywanego przez Visioscan 33
Ryc. 10. Dokumentacja fotograficzna- ustawienie na wprost, profil lewy, profil prawy 34
Ryc. 11. Dokumentacja fotograficzna- ustawienie lewe środkowo-boczne i prawe środkowo-boczne 34
Ryc. 12. Dokumentacja fotograficzna - sieć powierzchownych naczyń krwionośnych . 35

Tab. 1. Zawartość kwasu ferulowego w wybranych produktach spożywczych pochodzenia roślinnego 8
Tab. 2. Właściwości i wpływ kwasu ferulowego na skórę 16
Tab. 3. Charakterystyka grupy badanej 21
Tab. 4. Charakterystyka grupy I (peeling kwasem ferulowym) 22
Tab. 5. Charakterystyka grupy II (peeling kwasem ferulowym + mikronakłuwanie) 24
Tab. 6. Charakterystyka grupy III (peeling kwasem ferulowym + witamina C) 25

7 WYKAZ SKRÓTÓW

UVA - promieniowanie ultrafioletowe A (ang. *ultraviolet A*)

UVB - promieniowanie ultrafioletowe B (ang. *ultraviolet B*)

UVR - promieniowanie ultrafioletowe (ang. *ultraviolet radiation*)

IL - interleukiny

TNF-α - czynnik martwicy nowotworu α (ang. *tumor necrosis factor α*)

TEWL - transepidermalna utrata wody (ang *transepidermal water loss*)

KL - komórki Langerhansa

DNA - kwas deoksyrybonukleinowy (ang. *deoxyribonucleic acid*)

DEJ - połączenie skórno-naskórkowe (ang. *dermal-epidermal junction*)

mRNA - matrycowy rodzaj kwasu rybonukleinowego (ang. *messenger RNA*)

HLE - elastaza leukocytowa (ang. *human leukocyte elastase*)

MMP - metaloproteinazy (ang. *matrix metalloproteinases*)

AP-1 – kompleks białkowy (ang. *activator protein 1*)

ECM - istota podstawowa tkanki łącznej (ang. *etracellular matrix*)

GAG - glikozaminoglikany

HA - kwas hialuronowy (ang. *hyaluronic acid*)

FA - kwas ferulowy (ang. *ferulic acid*)

ArOH - związki fenolowe

$ROO^{\bullet}$ - rodnik nadtlenkowy

$RO^{\bullet}$ - wolny rodnik tlenowy

FAPR - rodnik fenoksylowy (ang. *ferulic acid phenoxyl radical*)

ROH - wodoronadtlenki, produkty nierodnikowe

$ArO^{\bullet}$ - rodnik fenoksylowy (aryloksylowy)

HAT - transfer atomu wodoru (ang. *hydrogen atom transfer*)
SPLET - sekwencyjny transfer elektronów z utratą protonów (ang. *sequential proton loss electron transfer*)
PCET - transfer elektronów sprzężony z protonem (ang. *proton-coupled electron transfer*)
ET-PT - przeniesie protonu poprzedzone przeniesieniem elektronu (ang. *electron transfer - proton transfer*)
LDL - lipoproteina o niskiej gęstości (ang. *low-density lipoprotein*)

BHT- butylohydroksytoluen

BHA - butylohydroksyanizol

INCI - Międzynarodowe Nazewnictwo Składników Kosmetycznych (ang. *International Nomenclature for Cosmetic Ingredients*)

VEGF - czynnik wzrostu śródbłonka naczyniowego (ang. *vascular endothelial growth factor*)

PDGF - płytkowy czynnik wzrostu (ang. *platelet-derived growth factor*)

HIF-1 - czynnik indukowany hipoksją 1 (ang. *hypoxia-inducible factor 1*)

TGF α i β - transformujący czynnik wzrostu (ang. *transforming growth factor α i β*)

FGF-2 - czynnik wzrostu fibroblastów (ang. *fibroblast growth factor-2*)

EGF - naskórkowy czynnik wzrostu (ang. *epidermal growth factor*)

LED - dioda elektroluminescencyjna (ang. *light-emitting diode*)

PDT - terapia fotodynamiczna (ang. *photodynamic therapy*)

FC – fototyp skóry według Fitzpatricka (ang. *Fitzpatrick skin phototype classification*)

SEsc - złuszczanie naskórka (ang. *scaliness*)

Ser - szorstkość naskórka (ang. *skin roughness*)

RBX – technologia aparatu Visia (ang. *red/brown subsurface analysis*)

JCR - ranking cytowalności czasopism (ang. *Journal Citation Reports*)

MPA- system pomiarowy (ang. *Multi Probe Adapter Systems*)

AFLS - skala oceny zaawansowania starzenia (ang. *Allergan Fine Line Scale*)

TCA - kwas trójchlorooctowy (ang. *trichloroacetic acid*)

POH - przebarwienia okołooczodołowe (ang. periorbital hyperpigmentation

8 ZAŁĄCZNIKI

8.1 Oświadczenia współautorów

UNIWERSYTET MEDYCZNY W ŁODZI

prof. dr hab. n. med. Helena Rotsztejn
Wydział Farmaceutyczny
Uniwersytet Medyczny w Łodzi
Zakład Kosmetologii i Dermatologii Estetycznej
Ul. Muszyńskiego 1, 91-151 Łódź

Łódź dn. 01.06.2022r.

OŚWIADCZENIE

Niniejsze oświadczenie dotyczy artykułu *The effectiveness of ferulic acid and microneedling in reducing signs of photoaging: A split-face comparative study* autorstwa Kamili Zduńskiej-Pęciak i Heleny Rotsztejn. Artykuł opublikowano w *Dermatologic Therapy* 2020 Nov;33(6):e14000. doi: 10.1111/dth.14000.

Oświadczam, że mój udział w tej pracy obejmował nadzór merytoryczny oraz przegląd manuskryptu.

KIEROWNIK
Zakładu Kosmetologii i Dermatologii Estetycznej
Katedra Kosmetologii
Wydział Farmaceutyczny
Uniwersytet Medyczny w Łodzi
90-151 Łódź, ul. Muszyńskiego 1
Prof. dr hab. n. med. Helena Rotsztejn

Prof. dr hab. n. med. Helena Rotsztejn

UNIWERSYTET MEDYCZNY W ŁODZI

prof. dr hab. n. med. Helena Rotsztejn
Wydział Farmaceutyczny
Uniwersytet Medyczny w Łodzi
Zakład Kosmetologii i Dermatologii Estetycznej
Ul. Muszyńskiego 1, 91-151 Łódź

Łódź..04.06.2022r.....

OŚWIADCZENIE

Niniejsze oświadczenie dotyczy artykułu *Two superior antioxidants: Ferulic acid and ascorbic acid in reducing signs of photoaging-A split-face comparative study* autorstwa Kamili Zduńskiej-Pęciak, Anny Kołodziejczak, Heleny Rotsztejn. Artykuł opublikowano w *Dermatologic Therapy* 2022 Feb;35(2):e15254. doi: 10.1111/dth.15254.

Oświadczam, że mój udział w tej pracy obejmował nadzór merytoryczny oraz przegląd manuskryptu.

KIEROWNIK
Zakładu Kosmetologii i Dermatologii Estetycznej
Katedra Kosmetologii
Wydział Farmaceutyczny
Uniwersytet Medyczny w Łodzi
90-151 Łódź, ul. Muszyńskiego 1
Prof. dr hab. n. med. Helena Rotsztejn

Prof. dr hab. n. med. Helena Rotsztejn

UNIWERSYTET MEDYCZNY W ŁODZI

prof. dr hab. n. med. Helena Rotsztejn
Wydział Farmaceutyczny
Uniwersytet Medyczny w Łodzi
Zakład Kosmetologii i Dermatologii Estetycznej
Ul. Muszyńskiego 1, 91-151 Łódź

Łódź...dn. 01.06.2022 r.....

OŚWIADCZENIE

Niniejsze oświadczenie dotyczy artykułu *Ferulic acid- a novel topical agent in reducing signs of photoaging* autorstwa Kamili Zduńskiej-Pęciak, Renaty Dębowskiej, Anny Kołodziejczak, Heleny Rotsztejn. Artykuł opublikowano w *Dermatologic Therapy* 2022.

Oświadczam, że mój udział w tej pracy obejmował nadzór merytoryczny oraz przegląd manuskryptu.

KIEROWNIK
Zakładu Kosmetologii i Dermatologii Estetycznej
Katedra Kosmetologii
Wydział Farmaceutyczny
Uniwersytet Medyczny w Łodzi
90-151 Łódź, ul. Muszyńskiego 1
Prof. dr hab. n. med. Helena Rotsztejn

Prof. dr hab. n. med. Helena Rotsztejn

UNIWERSYTET MEDYCZNY W ŁODZI

dr n. farm. Anna Kołodziejczak
Wydział Farmaceutyczny
Uniwersytet Medyczny w Łodzi
Zakład Kosmetologii i Dermatologii Estetycznej
Ul. Muszyńskiego 1, 91-151 Łódź

Łódź, dn. 01.06.2022r.

OŚWIADCZENIE

Niniejsze oświadczenie dotyczy artykułu *Two superior antioxidants: Ferulic acid and ascorbic acid in reducing signs of photoaging-A split-face comparative study* autorstwa Kamili Zduńskiej-Pęciak, Anny Kołodziejczak, Heleny Rotsztejn. Artykuł opublikowano w *Dermatologic Therapy* 2022 Feb;35(2):e15254. doi: 10.1111/dth.15254.

Oświadczam, że mój udział w tej pracy obejmował merytoryczną konsultację wyników oraz konsultację tekstu publikacji.

dr n. farm. Anna Kołodziejczak

Anna Kołodziejczak

UNIWERSYTET MEDYCZNY W ŁODZI

dr n. farm. Anna Kołodziejczak
Wydział Farmaceutyczny
Uniwersytet Medyczny w Łodzi
Zakład Kosmetologii i Dermatologii Estetycznej
Ul. Muszyńskiego 1, 91-151 Łódź

Łódź, dn. 04.06.2022r.

OŚWIADCZENIE

Niniejsze oświadczenie dotyczy artykułu *Ferulic acid- a novel topical agent in reducing signs of photoaging* autorstwa Kamili Zduńskiej-Pęciak, Renaty Dębowskiej, Anny Kołodziejczak, Heleny Rotsztejn. Artykuł opublikowano w *Dermatologic Therapy* 2022 Apr;29:e15543. doi:10.1111/dth.15543.

Oświadczam, że mój udział w tej pracy obejmował merytoryczną konsultację wyników oraz konsultację tekstu publikacji.

dr n. farm. Anna Kołodziejczak

Anna Kołodziejczak

dr n. biol. Renata Dębowska
Centrum Naukowo Badawcze Dr Irena Eris
ul. Puławska 107 A, 02-595 Warszawa

Łódź, 10.05.2022 r.

OŚWIADCZENIE

Niniejsze oświadczenie dotyczy artykułu *Ferulic acid- a novel topical agent in reducing signs of photoaging* autorstwa Kamili Zduńskiej-Pęciak, Renaty Dębowskiej, Anny Kołodziejczak, Heleny Rotsztejn. Artykuł opublikowano w *Dermatologic Therapy* 2022.

Oświadczam, że mój udział w tej pracy obejmował nadzór nad zbieraniem wyników badań.

dr n. biol. Renata Dębowska

Dębowska Renata

Elektronicznie podpisany przez Dębowska Renata
Data: 2022.05.10 22:44:29 +02'00'

UNIWERSYTET MEDYCZNY W ŁODZI

mgr Kamila Zduńska-Pęciak
Wydział Farmaceutyczny
Uniwersytet Medyczny w Łodzi
Zakład Kosmetologii i Dermatologii Estetycznej
Ul. Muszyńskiego 1, 91-151 Łódź

Łódź dn. 01.06.2022 r.

OŚWIADCZENIE

Niniejsze oświadczenie dotyczy artykułu *The effectiveness of ferulic acid and microneedling in reducing signs of photoaging: A split-face comparative study* autorstwa Kamili Zduńskiej-Pęciak i Heleny Rotsztejn. Artykuł opublikowano w *Dermatologic Therapy* 2020 Nov;33(6):e14000. doi: 10.1111/dth.14000.

Oświadczam, że mój udział w tej pracy obejmował: opracowanie koncepcji badania, wykonanie serii zabiegów z udziałem probantów, wykonanie pomiarów aparaturowych, wykonanie dokumentacji fotograficznej, zebranie, opracowanie statystyczne, interpretację i opis wyników badań, przygotowanie tekstu publikacji.

mgr Kamila Zduńska-Pęciak

Kamila Zduńska-Pęciak

UNIWERSYTET MEDYCZNY W ŁODZI

mgr Kamila Zduńska-Pęciak
Wydział Farmaceutyczny
Uniwersytet Medyczny w Łodzi
Zakład Kosmetologii i Dermatologii Estetycznej
Ul. Muszyńskiego 1, 91-151 Łódź

Łódź, dn. 01.06.2022r.

OŚWIADCZENIE

Niniejsze oświadczenie dotyczy artykułu *Two superior antioxidants: Ferulic acid and ascorbic acid in reducing signs of photoaging-A split-face comparative study* autorstwa Kamili Zduńskiej-Pęciak, Anny Kołodziejczak, Heleny Rotsztejn. Artykuł opublikowano w *Dermatologic Therapy* 2022 Feb;35(2):e15254. doi: 10.1111/dth.15254.

Oświadczam, że mój udział w tej pracy obejmował: opracowanie koncepcji badania, wykonanie serii zabiegów z udziałem probantów, wykonanie pomiarów aparaturowych, wykonanie dokumentacji fotograficznej, zebranie, opracowanie statystyczne, interpretację i opis wyników badań, przygotowanie tekstu publikacji.

mgr Kamila Zduńska-Pęciak

Kamila Zduńska-Pęciak

UNIWERSYTET MEDYCZNY W ŁODZI

mgr Kamila Zduńska-Pęciak
Wydział Farmaceutyczny
Uniwersytet Medyczny w Łodzi
Zakład Kosmetologii i Dermatologii Estetycznej
Ul. Muszyńskiego 1, 91-151 Łódź

Łódź dn. 01.06.2022r.

OŚWIADCZENIE

Niniejsze oświadczenie dotyczy artykułu *Ferulic acid- a novel topical agent in reducing signs of photoaging* autorstwa Kamili Zduńskiej-Pęciak, Renaty Dębowskiej, Anny Kołodziejczak, Heleny Rotsztejn. Artykuł opublikowano w *Dermatologic Therapy* 2022.

Oświadczam, że mój udział w tej pracy obejmował: opracowanie koncepcji badania, wykonanie serii zabiegów z udziałem probantów, wykonanie pomiarów aparaturowych, wykonanie dokumentacji fotograficznej, zebranie, opracowanie statystyczne, interpretację i opis wyników badań, przygotowanie tekstu publikacji.

mgr Kamila Zduńska-Pęciak

Kamila Zduńska-Pęciak

8.2 Zgoda Komisji Bioetyki

KOMISJA BIOETYCZNA PRZY UNIWERSYTECIE MEDYCZNYM W ŁODZI
Pl. Hallera 1B, 90-647 Łódź, tel. 0 785 911 596, 42 272-52-43, *bioetyka@umed.lodz.pl*

UCHWAŁA
KOMISJI BIOETYCZNEJ O PROJEKCIE EKSPERYMENTU MEDYCZNEGO
Numer RNN/81/19/KE z dnia 12 lutego 2019 r.
(przy korespondencji dotyczącej niniejszej decyzji prosimy powoływać się każdorazowo na powyższy numer i datę Uchwały)

Główny badacz i wykonawca:
Prof.dr hab.n.med. Helena Rotsztejn, mgr Kamila Zduńska-Pęciak, Zakład Kosmetologii i Dermatologii Estetycznej Uniwersytetu Medycznego w Łodzi, ul. Muszyńskiego 1, 91-151 Łódź

Tytuł badania:
Ocena porównawcza wpływu kwasu ferulowego oraz kwasu felurowego z mikronakłuwaniem na wybrane parametry skóry.

Na podstawie ustawy z dnia 5 grudnia 1996 r. o zawodach lekarza i lekarza dentysty (t. j. Dz. U. z 2017 r. poz. 125, z późn. zm.), ustawy z dnia 6 września 2001 r. Prawo farmaceutyczne (t.j. Dz. U. z 2016 r. poz. 2142 z późn. zm.), rozporządzenia Ministra Zdrowia z dnia 2 maja 2012 r. w sprawie wzorów dokumentów przedkładanych w związku z badaniem klinicznym produktu leczniczego oraz w sprawie wysokości i sposobu uiszczania opłat za złożenie wniosku o rozpoczęcie badania klinicznego (Dz. U. z 2012 r., poz.491), ustawy z dnia 20 maja 2010 r. o wyrobach medycznych (Dz. U. z 2017 r. poz. 211 ze zm.),rozporządzenia Ministra Zdrowia z dnia 17 lutego 2016 r. w sprawie wzorów wniosków przedkładanych w związku z badaniem klinicznym, wysokości opłat za złożenie wniosków oraz sprawozdania końcowego z wykonania badania klinicznego (Dz. U. poz. 208), rozporządzenia Ministra Zdrowia i Opieki Społecznej z dnia 11 maja 1999 r. w sprawie szczegółowych zasad powoływania i finansowania oraz trybu działania komisji bioetycznych (Dz. U. Nr 47 poz. 480), zarządzenia nr 8/2015 z 16 lutego 2015 r. Rektora Uniwersytetu Medycznego w Łodzi w sprawie wprowadzenia Regulaminu pracy Komisji Bioetycznej przy Uniwersytecie Medycznym w Łodzi oraz zarządzenia nr 57/2017 z dnia 5 września 2017 r. Rektora Uniwersytetu Medycznego w Łodzi w sprawie powołania Komisji Bioetycznej przy Uniwersytecie Medycznym w Łodzi po przeanalizowaniu wniosku, zapoznaniu się z projektem opinii dotyczącej zgłoszonego badania, w głosowaniu tajnym,
Komisja Bioetyczna przy Uniwersytecie Medycznym w Łodzi (wypełniając zobowiązania ICH GCP) uchwala, co następuje:

§ 1

1. Opiniuje wniosek **pozytywnie, bez zastrzeżeń** , na podstawie złożonych dokumentów, których wykaz określa załącznik nr 1. Uchwała wchodzi w życie z dniem podjęcia.

§ 2

Opinia dotyczy tylko rozpatrywanego wniosku z uwzględnieniem przedstawionego projektu. Każda zmiana i modyfikacja wymaga uzyskania odrębnej opinii. Wnioskodawca zobowiązany jest do informowania o wszelkich poprawkach, zdarzeniach niepożądanych oraz nieprzewidzianych okolicznościach.

Odwołanie od niniejszej uchwały wnosi się za pośrednictwem Komisji Bioetycznej przy Uniwersytecie Medycznym w Łodzi do Odwoławczej Komisji Bioetycznej, w terminie 14 dni od dnia otrzymania uchwały wyrażającej opinię.

Przewodniczący Komisji Bioetycznej
przy Uniwersytecie Medycznym w Łodzi

prof. dr hab. n. med. Józef Drzewoski

Lista obecności na posiedzeniu Komisji Bioetycznej przy Uniwersytecie Medycznym w Łodzi

w dniu 12 lutego 2019 r.

Lp.	Imię i nazwisko	Zawód, specjalność	Miejsce pracy	Podpis
1.	Prof. dr hab. n. med. Józef Drzewoski Przewodniczący Komisji	Lekarz medycyny, internista, diabetolog farmakolog kliniczny	Emerytowany profesor Uniwersytetu Medycznego w Łodzi	
2.	Ks. dr hab. Jan Wolski Z-ca Przewodniczącego Komisji	Duchowny, bioetyk	Wyższe Seminarium Duchowne w Łodzi	
3.	Prof. dr hab. n. med. Andrzej Głąbiński	Lekarz medycyny, neurolog	Klinika Neurologii i Udarów Mózgu UM w Łodzi	nb usprv.
4.	Prof. dr hab. n. med. Iwona Kłoszewska	Lekarz medycyny psychiatra	Klinika Psychiatrii Wieku Podeszłego i Zaburzeń Psychotycznych UM w Łodzi	
5.	Dr n.med. Maja Kufelnicka- Babout	Lekarz medycyny położnik, ginekolog	Klinika Perinatologii, I Katedry Ginekologii i Położnictwa UM w Łodzi	nb usprv.
6.	Prof. dr hab. n. med. Janusz Piekarski	Lekarz medycyny, chirurg onkolog	Klinika Chirurgii Onkologicznej UM w Łodzi	
7.	Prof. dr hab. n. med. Henryk Stępień	Lekarz medycyny, endokrynologia	Zakład Immunoendokrynologii UM w Łodzi	
8.	Dr hab. n. med. prof. nadzw. Marta Woldańska-Okońska	Rehabilitacja medyczna	Klinika Rehabilitacji i Medycyny Fizykalnej UM w Łodzi	nb usprv.
9.	Prof. dr hab. n. med. Krzysztof Zeman	Lekarz medycyny, pediatria, immunologia kliniczna	Klinika Pediatrii, Kardiologii Prewencyjnej i Immunologii Wieku Rozwojowego UM w Łodzi	
10.	Dr n. prawn. Rafał Budzisz	Prawnik	Uniwersytet Łódzki w Łodzi	
11.	Mgr Elżbieta Kubańska	Pielęgniarka	Pracownik emerytowany	
12.	Mgr Elżbieta Piotrowska-Rutkowska	Farmaceutka	Naczelna Izba Aptekarska, ul. Długa 16 w Warszawie	
13.	Dr n. med. Elżbieta Jaszczuk	Lekarz medycyny, anestezjologia i intensywna terapia	Przedstawicielka Okręgowej Rady Lekarskiej w Łodzi	

8.3 Formularz świadomej zgody

Załącznik nr 3- **Formularz świadomej zgody badanego**

Na udział w badaniu pt: „Ocena porównawcza wpływu kwasu ferulowego oraz kwasu ferulowego z mikronakłuwaniem na wybrane parametry skóry".

Ja (imię i nazwisko badanego).....oświadczam, że otrzymał/em/am i zapoznał /em/am się z treścią informacji dla badanego. Doktorantka przeprowadzająca badanie udzieliła mi wyczerpujących odpowiedzi na moje pytania. Jestem wystarczająco poinformowany/a.

Świadomie i dobrowolnie wyrażam zgodę na wykonanie serii zabiegów obejmujących aplikację peelingu chemicznego z kwasem ferulowym oraz mikronakłuwania skóry. Wiem, że mogę cofnąć swoją zgodę w dowolnej chwili bez wpływu na opiekę lekarską jakiej będę potrzebować.

Zgadzam się na przetwarzanie moich danych osobowych zgodnie z ustawą o ich ochronie.

Podpisy:

Badanego .....

Studenta.....

Łódź, dnia.....

8.4 Publikacje poglądowe

Received: 30 May 2018 | Revised: 3 August 2018 | Accepted: 12 August 2018
DOI: 10.1111/dth.12714

WILEY DERMATOLOGIC THERAPY

REVIEW ARTICLE

Is skin microneedling a good alternative method of various skin defects removal

Kamila Zduńska | Anna Kołodziejczak | Helena Rotsztejn

Chair of Cosmetology, Department of Cosmetology and Aesthetic Dermatology, Faculty of Pharmacy, Medical University of Łódź, Łódź, Poland

Correspondence
Anna Kołodziejczak, Chair of Cosmetology, Department of Cosmetology and Aesthetic Dermatology, Faculty of Pharmacy, Medical University of Łódź, Muszyńskiego 1 Street, 91-151 Łódź, Poland
Email: anna.kolodziejczak@umed.lodz.pl

Funding information
Medical University of Łódź, Grant/Award Number: 503/3-066-01/503-31-001

Abstract

Skin microneedling accelerates the process of skin regeneration through the creation of numerous microinjuries which emerge when skin is deeply punctured with very thin needles. The whole procedure evokes various reactions which can be divided into three major phases: inflammation, proliferation, and remodeling. It activates platelet growth factors which are responsible for the stimulation of fibroblasts to produce collagen and elastin. Moreover, skin breakdown enhances penetration of active ingredients. Treatment can be performed with the use of different devices, all equipped with needles of various lengths. Due to the fact that skin microneedling stimulates the synthesis of significant rebuilding and structural skin elements (collagen, elastin, proteoglycan), it is used in the treatment of many skin defects of different etiologies (e.g., photoaging, wrinkles, loss of elasticity, hypo- or hypertrophic scars, pigmentation changes, infraorbital dark circles, teleangiectasia, stretch marks, cellulite, alopecia, and vitiligo). In order to accelerate postsurgical regeneration and/or to enhance effects, microneedling is combined with the application of UV light (photodynamic therapy with ALA), LED light, platelet-rich plasma, chemical peels, stem cells, retinoids and other pharmaceuticals, and vitamins. High effectiveness, limited number of side effects, and short recovery time, make skin microneedling a popular cosmetic, and medical treatment.

KEYWORDS

dermapen, dermarollers, mesotherapy, microneedling, revitalization

1 | INTRODUCTION

The use of procedures stimulating the revitalization of skin, including fractional methods: fractional microneedling radiofrequency, fractional microneedling radiofrequency technology combined with LED light (light-emitting diode) and non-ablative, and ablative fractional laser therapy, fractional IR (infrared light) seems to be essential. Nevertheless, none of these treatments do not promote the transfer of active ingredients through the epidermal barrier. Mesotherapy can be used in order to increase the transdermal absorption of active substances.

Mesotherapy (intradermotherapy) involves intradermal or subcutaneous administration of small doses of medicinal substances to the affected spots. Currently, drugs are rarely introduced; instead multi-ingredient preparations are preferred. Mesotherapy was initiated by Michel Pistor in the 1960s in France. Pistor used spot multiple drug injections to treat pain syndromes and vascular disorders (Konda & Thappa, 2013; Sarkar, Garg, & Mysore, 2011). Mesotherapy as a treatment was first used in aesthetic medicine in the 70s. Microneedling is one of the mesotherapy types, known also as microneedle mesotherapy. The method has been promoted by Desmond Fernandes in the 90s (Singh & Yadav, 2016).

Cosmetic and biotech industries are constantly developing more and more sophisticated active ingredients designed to neutralize all kinds of skin defects. The mechanism of action of the active compounds is usually proven and supported by the results of numerous studies, but their use in practice does not always bring satisfactory results. Transfer of most active substances through the epidermal barrier may be difficult. Some of the substances undergo decomposition on the surface of the epidermis and some during the transdermal penetration. As a result, only a small percentage of them have the chance to reach the deeper layers. This can lead to low bioavailability of the active substances and, consequently, to unsatisfactory therapeutic effects. Mechanical puncturing of the skin with thin needles breaks skin's continuity and allow for increased penetration. Many studies involving transdermal delivery of drugs into different skin layers using microneedling confirmed an increased concentration of lipophilic and hydrophilic

 © 2018 Wiley Periodicals, Inc.

pharmaceuticals as well as macromolecules in the layers under the stratum corneum. Histopathological studies suggest that thin needles separate cells without damaging them (Aust, Fernandes, Kolokythas, Kaplan, & Vogt, 2008; Fernandes, 2005). Furthermore, controlled skin damage stimulates natural self-repair mechanisms, resulting in increased synthesis of substances that are important building blocks (e.g., collagen, elastin, hyaluronic acid, etc.). Due to the possibility of inclusion of multi-component preparations in the treatment, microneedling is used in the leveling of skin defects, such as photoaging, wrinkles, loss of elasticity, hypo- or hypertrophic scars, pigmentation changes, teleangiectasia, stretch marks, cellulite, alopecia, and vitiligo. The contraindications comprise: local skin infections, active herpes simplex, keloids, healing and coagulation disorders, collagen disorders, solar dermatitis, and malignancy (Šuca, Zajíček, & Vodsloň, 2017). Savita Y. et al. observed that their patient possibly developed contact dermatitis to nickel metal which leached out from the needles of the dermaroller. This case indicates that the information on history of any allergic reactions to metals and active cosmetic ingredients should be obtained from all patients (Yadav & Dogra, 2016).

The procedure is being conducted under sterile conditions. Directly after the treatment, a reddening, local edema, and skin tenderness occur, and it may be accompanied by minimal, short-term bleeding. These symptoms can last for 24–48 hr. The wound should be appropriately covered with an occlusive dressing and an antiseptic ointment. Microneedle mesotherapy also seems to be a good option for those whose recovery takes long. Appropriate routine hygiene and sun protection is required for following microneedling (Šuca et al., 2017).

Potential long-term effects are currently unknown, but inappropriate use of such procedures could cause problems, for example, the application of a non-sterile topical product. Moreover, only licensed and tested therapeutics or cosmetics, designed for this intended purpose should be used for microneedling treatment (McCrudden et al., 2015).

2 | MOST COMMONLY USED DEVICES

The devices that are most commonly used in mesotherapy are dermarollers. At the beginning insulin syringe was used, however, it was difficult to adjust the depth manually. Therefore, now dermarollers and dermapens are used. The treatment consists of controlled skin damage through intensive mechanical puncture. A rotating shaft containing needles rolls along the skin in different directions. Depending on the purpose, dermarollers with different needle lengths are used. Dermarollers with very short needles are used within the epidermis at a depth of 0.1–0.5 mm and so-called surgical needles, which require intensive anesthesia, are used at a depth of 3–4 mm. The most commonly used needles are 1–2 mm long (Badran, Kuntsche, & Fahr, 2009; McCrudden et al., 2015) Dermaroller penetrates into skin at the angle of 45°.

In order to treat small areas of the body (e.g., the eye area, the area above the upper lip, single scars, and stretch marks), Dermastamps (miniature versions of Dermarollers), are used. The small diameter of the shaft ensures precise operation, making it easier to reach problematic areas (McCrudden et al., 2015; Singh & Yadav, 2016).

Dermapens are also used in microneedling mesotherapy. Skin puncturing is done by automatic, pulsating movement of the needles protruding from the replaceable tip. The smaller number of needles, the ability to adjust their length (0.25–2.5 mm), and the speed of eject (low 412, fast 700 ejections/min) make the device easy to use, increasing at the same time accuracy and precision. This gives the opportunity to work on all areas of the skin, without changing the instrument. For example, one could perform 0.5 mm punctures around the eyes and then 2 mm on the cheeks (Badran et al., 2009; Singh & Yadav, 2016). Dermapen penetrates through the epidermis at a perpendicular angle and therefore it reaches optimal depth and it is suitable for face and delicate areas. Furthermore, dermapen provides the opportunity to work in specific areas. The pressure of the device on the skin is not as important as in the case of dermarollers (Arora & Gupta, 2012).

Also, the needle length was an important factor. The use of a needle length of over 1.5 mm enabled drug penetration into the receptor compartment of the dermis. Transdermal penetration of the drug was facilitated with the use of a needle length of 0.5 mm. Drug accumulation in the stratum corneum occurred when a needle penetrating into the depth of 0.15 mm was used. A needle length of up to 0.25 mm is safe for use even in a home environment but cosmetologists/physicians in a healthcare setting are expected to use a needle length of 0.5 mm and more. A similar penetration of pharmaceuticals was confirmed also with the use of dermaroller just before the substance application (Šuca et al., 2017). Moreover, the increase in transepidermal drug delivery is observed for at least 72 hr after the procedure (Lima, Lima, Paixão, & Miot, 2017). The microtraumatization creates micropores, which results in increased transdermal water loss (Šuca et al., 2017), however, the result of the study has demonstrated that prompt recovery of skin barrier function is achieved within several hours from device usage (Shah, Shah, Solanki, & Raval, 2017).

3 | ACTION MECHANISMS

The micropuncture action mechanism is used to induce controlled inflammation in the skin through numerous microprisms created during condense punctures with thin needles. Puncturing the skin with needles of appropriate length can cause damage to superficial blood vessels and results in microbleeding. This starts a process that is analogous to wound healing process. Microneedling causes microscopic breaks in the blood vessels just below epidermis. In this process blood platelets (responsible for blood clotting) are released and the production of collagen, elastin, and growth factors is promoted (Arora & Gupta, 2012). Microneedling initiates a series of skin reactions which can be divided into three main phases: inflammation, proliferation, and remodeling (McCrudden et al., 2015).

3.1 | The phase of inflammation

The inflammatory stage is relatively short (up to 72 hr from injury) and includes clot formation, cytokine and growth factors infiltration

into the wounded area as well as the activation of immune cells (Buganza & Kuhl, 2013). The most important process associated with microneedling is platelet activation (as a result of discontinuation of blood vessels). This leads to the release of many growth factors, including platelet-derived growth factor (PDGF), transforming growth factor α (TGFα), transforming growth factor β (TGFβ), fibroblast growth factor-2 (FGF-2), and epidermal growth factor (EGF), which all strongly stimulate fibroblasts to produce collagen and elastin (Koca, Cecen, Gurgen, Sayin, & Cetin, 2013; McCrudden et al., 2015). Immune cells (leukocytes, neutrophils, macrophages) clean the site of injury from possible contaminants and bacteria. Within 1 week from the injury, these cells undergo apoptosis and the wound environment changes dramatically (Demidova-Rice, Hamblin, & Herman, 2012).

3.2 | The phase of proliferation

The main processes that take place in the proliferative phase which lasts 2–3 weeks, are epithelialization and replacement of fibrin clot with granulation tissue (Buganza & Kuhl, 2013). Newly developed granulation tissue is predominantly composed of fibroblasts, collagen, and hyaluronic acid. Both the migration and secretion of fibroblasts, as well as the reconstruction of the extracellular matrix, are regulated by Matrix Metalloproteinases (MPPs), interleukin, and growth factors (TGF-β, PDGF, EGF) (Greaves, Ashcroft, Baguneid, & Bayat, 2013; McDougall, Dallon, Sherratt, & Maini, 2006). Collagen is one of the most important proteins synthesized during the production of new tissue. The proliferation of keratinocytes contributes to the deposition of collagen Type IV and VII, while fibroblasts stimulate collagen Type I and III synthesis. Collagen Type I and III deposited on fibronectin participates in the replenishment of tissue defects increasing its extensibility. Collagen type III predominates in granulation tissue which is a typical rebuilding tissue after mechanical injuries (Gabbiani, 2003). Histopathological examination of skin subjected to a series of microneedling procedures demonstrated fourfold increase in the amount of collagen and elastin fibers (Nair & Arora, 2014). What is more, the structure of the newly formed collagen fibrils does not differ from the structure of collagen fibrils in undamaged skin (Aust et al., 2008). Parallel to the process of neocollagenesis, angiogenesis (the formation of new blood vessels) occurs. This causes that the skin is more oxygenated. The most important cytokines involved in the process of vascularization of wounded tissues are: vascular endothelial growth factor (VEGF), FGF-2- fibroblast growth factor (FGF) 2, and platelet-derived growth factor (PDGF) (Demidova-Rice et al., 2012; Kajdaniuk, Marek, Fołtyn, & Kos-Kudła, 2011).

3.3 | The phase of remodeling

During the remodeling phase, the extracellular matrix is further transformed. At first, collagen Type III is mainly synthesized, but then it gradually converts into collagen Type I. Skin becomes thicker and more durable and it regains the correct color and texture (Fernandes, 2005). Histopathological examination of the skin after microneedling shows a significant increase in the thickness of the granular layer of the epidermis, with no change in the thickness of the dermis (Aust et al., 2008).

Another theory that explains the mechanism of micropuncturing is related to the change in the membrane potential of a cell during the contact with the needle. The membrane resting potential is on average −70 mW. Inserting the needle in the closest vicinity of the cell, immediately changes the membrane potential to −100 mW, which in turn significantly increases cellular activity and results in the release of protein, potassium, and growth factors. Release of these kinds of compounds into the intercellular space stimulates the migration of fibroblasts to the wounded areas and promotes the production of collagen, elastin, and proteoglycans (Liebl & Kloth, 2012).

4 | MAIN INDICATIONS FOR THE APPLICATION OF MICRONEEDLING

4.1 | Skin aging symptoms

The attempts to reduce or delay the signs of skin aging should include methods which are adjusted to the nature of changes and which potential benefits outweigh the risk of side effects. Many years of studies have resulted in the development of novel techniques which are replacing the old, invasive ones. Chemical peels or ablation laser-otherapy which have been performed to stimulate revitalization of the skin are today replaced by less invasive methods which do not require a postoperative period. More and more authors are paying attention to the side effects of treatments such as ablative laser therapy or chemical peels in high concentrations (Ross et al., 2000). Deep vaporization of the epidermis up to the dermis produces significant inflammation and strongly stimulates the fibroblasts to produce large amounts of collagen in a short time, but not in the correct regular network. It may be associated with greater future susceptibility to skin photodamage, including pigmentation disorders (Laws, Finley, McCollough, & Grabski, 2012; Rawlins, 2006). Scarring may also occur. Researchers have demonstrated that transforming growth factor β (TGFβ) is one of the most important factors involved in scar formation. Two types of TGF-β, TGF-β1, and TGF-β2, predominantly participate in the healing process with scar formation. These factors are also responsible for the formation of a dense collagen structure. TGF-β3, which indirectly participates in the formation of normal, stretch-resistant collagen fibers, is responsible for healing without scarring. Effective anti-aging treatment should, therefore, activate mainly TGF β3, without stimulating other types of TGF (Bandyopadhyay et al., 2006; Ferguson & Kane, 2004). In light of current knowledge, microneedle mesotherapy is a method that enables skin healing during the regeneration process without the formation of scarring, which contributes to the increase of TGF-β3 (Aust et al., 2008; Aust et al., 2010).

In medical literature, microneedling is referred to as "medical skin needling" (Zeitter et al., 2014), collagen induction therapy (CIT) (Fabrocini, DeVita, & Pastore, 2012) and percutaneous collagen induction (PCI) (Fernandes & Signorini, 2008). It should be borne in mind, however, that both CIT and PCI involve appropriate needle-length operation that reaches blood vessels in the skin, causing the microbleeding. Many authors believe that this operation is necessary in order to induce proper skin regeneration process associated with

increased collagen and elastin synthesis mediated by platelet growth factors (Fabrocini et al., 2012; Fernandes & Signorini, 2008).

Full effect of the series of microneedling procedures involving in the lowering of wrinkles visibility, and an improvement of skin elasticity, is achieved after about 3 months, due to the length of the neocollagenesis process (Fabrocini et al., 2012).

According to Fernandes D, the use of preparations rich in vitamin A and C together with microneedle mesotherapy is required in order to take full advantage of skin regenerative potential. In his opinion, only such a combination provides the best stimulation of the synthesis of new collagen (Aust et al., 2008). In case of persons with significantly thickened horny layer (stratum corneum) of the epidermis, it is recommended to precede microneedling with a delicate chemical peel (Fernandes, 2005).

El-Domyati et al. have demonstrated the effectiveness of microneedle mesotherapy in the fight against aging signs. Histopathological examinations of skin specimens taken from patients who underwent a series of six microneedling procedures (1 mm in depth) at 2-week intervals showed significant changes within both the epidermis and dermis. The prickle cell layer (stratum spinosum) of the epidermis thickened, which affected the development of rete ridges and the increase of skin layers integrity. The amount of collagen Type I, III, and VII increased significantly. Moreover, changes in skin structure and total content of elastin were observed. Irregular elastin aggregation formed in the process of solar elastosis were reduced, while tropoelastin levels increased, resulting in the rise of correctly arranged elastin fibers. These all resulted in a significant reduction in wrinkles, increased tension and elasticity, and improved face oval. In reviewing participants' subjective assessment, this treatment was considered to be extremely effective in the reduction of aging signs (El-Domyati et al., 2015a).

Additionally, Fabrocini et al. showed a significant improvement in the appearance of wrinkles around the mouth, after two microneedling procedures. Using the Wrinkle Severity Rating Scale, the depth of wrinkles was determined to have decreased twofold after 30 weeks from the second treatment. Moreover, indirect profilometry revealed skin smoothing by over 30% (Fabrocini et al., 2012).

4.2 | Hypotrophic scars

Microneedling as a method for modification of hypotrophic scarring—opens another possibility to improve the resulting scar. In comparison to other methods, such as ablative laser therapy, during this procedure no artificial necrotic tissue is created and no significant inflammatory reaction occurs during the healing process. Microneedling treatment also improves the quality of patients' life (Badran et al., 2009; Šuca et al., 2017).

The exact mechanism of microneedling impact on scars is not fully understood. It is believed that matrix metalloproteinases (MMPs) play the main role in the remodeling of scar tissue. MMPs belong to the family of proteolytic enzymes, which comprises also collagenase, an enzyme involved in collagen degradation (Liebl & Kloth, 2012). In response to scar microneedling, MMPs are activated, and consequently, degradation of abnormally arranged collagen fibers occurs. Collagen degradation stimulates fibroblasts to produce new procollagen fibers which, during maturation, form a network. The process of new blood vessels formation occurs simultaneously with neocollagenesis and therefore the tissue is better supplied in blood and better oxygenated. Studies have demonstrated higher efficiency and faster effects of microneedling in case of atrophic scars (e.g., acne scars) than in the case of hypertrophic ones. Significant improvement after a series of three mesotherapy treatments are visible after 10–20 weeks, while the remodeling of hypertrophic scars and keloids lasts up to several months (Liebl & Kloth, 2012).

El-Domyati et al. studied the effectiveness of microneedling in the reduction of acne scars. Ten patients underwent a series of six procedures with the use of Dermarollers at 2-week intervals. The effectiveness of this treatment was found to be very high, both in participants' subjective assessment and in the histopathological examination of skin specimens; there was 80–85% improvement in skin general condition and skin plotting. The epidermis significantly thickened and the amount of extracellular matrix proteins increased. After 3 months, the highest growth of Type I collagen, followed by Type III and VII collagen, was observed. The content of elastin decreased, however, and many molecules of so-called tropoelastin (a precursor of mature elastin fibers) appeared. This treatment was considered by both study participants and dermatologists to be extremely effective in the fight against scars (El-Domyati et al., 2015b).

Microneedle mesotherapy is also used in people with darker skin phototypes, in whom other available methods produce many side effects, including hyperpigmentation and discoloration. Dogra et al. demonstrated that the series of five microneedling procedures significantly reduced scar depth and smoothed skin in people with Fitzpatrick skin phototype IV and V, without causing any significant side effects. According to the authors' acne scar assessment score, scars were reduced by 50–75% (Dogra, Yadav, & Sarangal, 2014).

4.3 | Stretch marks

Nassar et al. conducted a study involving a group of 40 women with multiple stretch marks of different origins. The aim of their study was to compare microdermabrasion treatment, which has been used for scar removal for a long time, with a relatively new approach—microneedling. Histopathological analyses of skin demonstrated an increase in the amount of collagen and fibroblast and epidermal thickening by 90% in groups of patients who underwent three microneedle mesotherapy procedures. The improvement observed in the group treated with microdermabrasion was only 50%. Thus, it has been revealed that microneedling is more effective and brings faster effects in the reduction of stretch marks (Nassar, Ghomey, El-Gohary, & El-Desoky, 2016). Microneedling was also reported to be more effective in the treatment of stretch marks than fractional CO_2 laser ablation. In the study of Khater et al., the improvement after a series of three mesotherapy treatments was estimated as "good" in 30% of participants, as "moderate" in 40% of participants, and as "poor" in 20% of participants. In 10% of participants who underwent three laser treatments the improvement was "good," in 30% it was "moderate," and in 10% it was "poor." Fifty percent of persons did not observe any improvement after laser therapy, while only 10% did not benefit from mesotherapy. The above results were obtained by comparing

photographs taken before and after a series of treatments, as well as by using questionnaires assessing the satisfaction of participants with obtained effects (Khater, Khattab, & Abdelhaleem, 2016).

4.4 | Alopecia

Diagnostics and the final diagnosis are of great importance while determining the method of alopecia treatment. The treatment of hair loss involves mainly general and topical medications (minoxidil, finasteride, and antiandrogens), immunotherapy, phototherapy, and surgical methods of hair transplantation. Many available formulations are, however, associated with possible side effects in the form of irritation of head skin, libido lowering, and erectile dysfunction (Gupta, Carviel, & Abramovits, 2017). Therefore, other treatments for this common disease are still being sought out.

According to many authors, microneedling is one method supporting and greatly increasing the effectiveness of alopecia treatment. Growth factors released during skin microneedling stimulate hair matrix cells promoting greater activity and more frequent division. At the same time, the expression of genes responsible for hair growth is increased, which results in faster and more intense hair growth. Moreover, microneedle mesotherapy enhances the penetration of active ingredients used in the treatment of alopecia (Dhurat et al., 2013).

Dhurat et al. demonstrated a much higher efficacy of minoxidil when it was used in combination with microneedling, as opposed to the use of this drug alone. Their study included 100 men with signs of alopecia. Their scalps were shaved off and hair count was done in marked areas with the use of images taken at fixed focus. The same procedure was repeated after a series of treatment. In patients who underwent a combined treatment (microneedling + minoxidil) a significantly greater amount of hair was observed after a series of treatments when compared to a small increase in the number of hair follicles in patients using only minoxidil. In the subjective evaluation of study participants, 82% of subjects in the combined treatment group reported more than 50% improvement while in Minoxidil group the same result was observed only in 4.5% patients. In the assessment of independent investigators evaluating the effects of the study, combination therapy was associated with improvement by 2–3 points in the standardized 7-point rating scale. None of subjects in the drug group experienced similar results (Dhurat et al., 2013).

Studies have demonstrated that microneedling is also effective in patients poorly reacting to finasteride and minoxidil, as these drugs, when used for several years, only suppressed the progressive alopecia without stimulating new hair growth. The inclusion of microneedle mesotherapy into the treatment increased the effectiveness of therapy by 2–3° in the standardized 7-point rating scale. Subjects observed 50–75% improvement (Dhurat & Mathapati, 2015).

4.5 | Hyperpigmentation

Despite the availability of many skin brightening substances, some types of hyperpigmentation are particularly difficult to remove, which prompts physicians to resort to other methods (e.g., microneedle mesotherapy) (Lima, 2015). The effectiveness of microneedling in the removal of hyperpigmentation has been confirmed by numerous studies, though the mechanism of action remains unknown. It has been suggested that the thickening of skin and epidermis following a series of microneedling procedures results in the reduction of hyperpigmentation visibility (Sahni & Kassir, 2013). Additionally, thickened epidermis can pose additional protection against UV damage (Lima et al., 2017. Other researchers believe that MMPs play a key role in this process; however, the exact impact of these enzymes on melanogenesis remains unexplained (Singh & Yadav, 2016).

Melasma is a frequently occurring discoloration, which is hard to remove using available brightening methods. Lima E.A. demonstrated that one microneedle mesotherapy (needles with the length of 1.5 mm) significantly reduced this type of hyperpigmentation. According to the accepted four-step improvement assessment scale, the improvement in all 22 participants was "good" or "very good." Furthermore, 11 subjects from the study group were reevaluated after 24 months from the procedure. The analysis of photographic documentation revealed that the brightening effect was maintained (Lima, 2015). Budamakuntel et al. also demonstrated the effectiveness of microneedling in combination with the active substance tranexamic acid in melasma brightening. Their study, comprised of 60 participants, compared the effects of subcutaneous injection of acid with injection of the same substance in combination with microneedling. The results were obtained using melasma area severity index (MASI) and participants' subjective assessment. After three treatments performed every month, the improvement in the first group was 35.72%, while in the second group it was 44.41%. Brightening by more than 50% was demonstrated in 41.38% of subjects in the microneedling group and in 26.09% in the injection group. The combination of microneedling with tranexamic acid was found to be more effective than subcutaneous injections of this substance alone (Budamakuntla et al., 2013). The oral use of tranexamic acid in the dose of 750 mg per day for 3 months gives very good results, and its combination with microneedling may further improve its effects.

Lima V.A.E. et al. studied clinical and histologic alterations stimulated by skin microneedling in patients with facial melasma. A pilot trial included six patients participating in two sessions of microneedling (1.5 mm) every month. Improvement of melasma was observed in all subjects. There was a significant reduction in MELASQoL (−55%), MASI score (−70%) and increase in L^* (+13%) colorimetric value ($p < 0.03$). In all patients, epithelium thickening, decrease in melanin pigmentation and densification of upper dermis collagen were seen ($p = 0.03$). Authors claimed that microneedling promoted clinical and histological improvement of refractory melasma (Lima et al., 2017).

4.6 | Vitiligo

Several treatment modalities had been used for vitiligo therapy; however, its optimal management has not yet been identified. Microneedling is also used in the treatment of vitiligo. Mina M. et al. have studied the efficacy of microneedling in combimation with 5-flurouracil in comparison to its efficacy in combination with tacrolimus in the treatment of vitiligo. Twenty-five patients were subjected to microneedling of two patches of vitiligo with dermapen, followed by the application of 5-fluorouracil to one patch and tacrolimus on the other patch. Patients had 12 sessions of treatment in 2 weeks

intervals. Microneedling combined with drugs was found to be safe and effective treatment of vitiligo. However, in the case of 5-fluorouracil a greater percentage of repigmentation was achieved in comparison to tacrolimus (Mina, Elgarhy, Al-Saeid, & Ibrahim, 2018).

Korobko I et al. performed a pilot comparative study of topical latanoprost and tacrolimus in combination with narrow-band ultraviolet B phototherapy and microneedling for the treatment of non-segmental vitiligo. Symmetrical lesions of 24 patients were treated with model Dermaroller device with 0.5 mm needle length, and latanoprost (0.005% solution) or tacrolimus (0.1% ointment) were applied immediately after the procedure. Four microneedling procedures were carried out in 1-week intervals. Patients were prescribed three NB-UVB phototherapy sessions in the period between microneedling procedures. After the last microneedling, lesions were photographed and evaluated by the dermatologist. For the next 2 months, patients were prescribed NB-UVB phototherapy (every other day), and the application of latanoprost and tacrolimus, respectively, every day between phototherapy sessions. After the completion of therapy, percentage of lesion repigmentation was analyzed in all patients. Authors could not make final decision whether microneedling improved therapeutic efficiency of topical agents (Korobko & Lomonosov, 2016).

4.7 | Infraorbital dark circles

There are many different types of treatments available for dark circles including: lasers, chemical peels, bleaching creams, autologous fat transplantation, and injectable fillers. Nevertheless, none has been found to be entirely satisfactory. Superficial chemical peels and microneedling have become alternative method. The aim of a study performed by Kontochristopoulos G et al. was to assess the efficacy and safety of a combination of microneedling (0.5–1 mm Dermaroller) with the application of 10% trichloroacetic acid peels (5-min application) for the treatment of dark circles. Thirteen female patients with infraorbital dark circles were included in the study. The effects were assessed on the basis of patient and physician global assessment and photo-documentation. Almost all patients observed significant aesthetic improvement (Kontochristopoulos et al., 2016).

4.8 | Combined treatments

In order to achieve greatest rejuvenating effects, it is best to combine microneedle mesotherapy with other available methods.

Some studies also reported beneficial effects of microneedling in combination with retinoids. Kim et al. used histopathological analyses to demonstrate that the use of 0.025% tretinoin during microneedle mesotherapy provides much better results, including increased skin thickness, densification of collagen fibers, and enhanced regeneration, than either of these methods alone (Kim, Park, Jung, & Choi, 2012). The combined use of needling and tretinoin is best for striae.

The combination of microneedle mesotherapy with stem cells is another procedure that has been analyzed. Synergistic actions of platelet growth factors secreted as a result of microneedling and the activation of growth factors and cytokines by stem cells result in significantly stronger stimulation of fibroblasts for the synthesis of new collagen units in comparison to mesotherapy itself. Moreover, a brightening of discolorations and a decrease in erythema intensity are observed following the series of treatments (Lee et al., 2014; Seo, Kim, Lee, Yoon, & Lee, 2013).

To strengthen the effect of this treatment, it can be combined with chemical peeling. It was demonstrated that the use of peeling with 35% glycolic acid in the period between mesotherapy therapies resulted in greater improvement (by 62%) in scar appearance in comparison to microneedling alone (improvement by 31.33%). Obtained results were based on scale determining the level of scarring severity (Echelle d'Evaluation clinique des Cicatrices d'acné classification). The procedure was also performed on patients with darker skin phototypes (Fitzpatrick skin phototype V) and it did not cause side effects (Sharad, 2011).

Microneedling is an established treatment for scars, while the efficacy of platelet-rich plasma (PRP) has not been much explored. Mohd A. et al. studied the efficacy and safety of PRP combined with microneedling in the treatment of 50 patients with atrophic acne scars. Microneedling was performed using a standard roller device with 192 needles, each of 1.5 mm in size on both halves of the face. PRP was topically applied on right half of the face, while the left half of the face was treated with distilled water. Three treatment sessions were performed in 1 month intervals. Authors concluded that PRP was efficient in the management of atrophic acne scars and it can be combined with microneedling to enhance the final clinical outcomes. However, more research is required in order to standardize the combined use of PRP and microneedling (Asif, Kanodia, & Singh, 2016).

There are very few studies evaluating the efficacy of PRP alone or in combination with microneedling in hair restoration. Kaksha B Shah et al. performed a study aiming at comparing the efficacy of (A) topical minoxidil (5%) alone and (B) minoxidil in combination with microneedling with PRP. They performed objective and subjective evaluation based on photographic evidence and clinical improvement. Fifty patients were randomly divided into two groups of 25 patients. There was a significant improvement ($p < 0.05$) in Group B as compared to Group A. Microneedling with PRP is safe and effective for the management of androgenetic alopecia (Shah et al., 2017).

Microneedling combined with PRP or vitamin C seems to be a promising treatment of atrophic acne scars. Simran Chawla in her study compared the efficacy of microneedling with PRP in comparison to microneedling with topical vitamin C in the treatment of atrophic post acne scars in a split face design. Twenty-three of 30 patients achieved the reduction of scarring. Overall results were better for microneedling with PRP, however, microneedling with vitamin C also showed improvement with respect to firmness of skin and both hyperpigmentation and melasma (Chawla, 2014).

Microneedling has been used in combination with photodynamic therapy (PDT) to enhance topical delivery of aminolevulinic acid (ALA). This procedure used red light and broadband pulsed light which allowed for deeper activation of ALA. It has been used in the treatment of actinic keratosis (McCrudden et al., 2015).

Another possible option is to use microneedling (rollers, pens) with LED (light emitting diode), however, there are no studies confirming the benefits of these devices in comparison to non-LED microneedling ones (McCrudden et al., 2015).

5 | CONCLUSION

Microneedle mesotherapy is an effective method for the elimination of skin defects, both in teenagers fighting with acne scars and elderly persons who wish to reduce the signs of aging. In light of current knowledge, microneedling seems to be a safe procedure with a low risk for complications.

CONFLICT OF INTEREST

The authors declare no conflict of interest. The authors themselves are responsible for the content and writing of the paper.

ACKNOWLEDGMENTS

This work was supported by statutory research activity Department of Cosmetology and Aesthetic Dermatology, Faculty of Pharmacy, Medical University of Łódź No.: 503/3-066-01/503-31-001.

CONTRIBUTION OF AUTHORS

We declare that this work was done by the authors named in this article and all liabilities pertaining to claims relating to the content of this article will be borne by the authors.

ORCID

Anna Kołodziejczak http://orcid.org/0000-0002-7799-9188

REFERENCES

Arora, S., & Gupta, P. (2012). Automated microneedling device – A new tool in dermatologist's kit – A review. *Journal of Pakistan Association of Dermatologists*, *22*, 354–357.

Asif, M., Kanodia, S., & Singh, K. (2016). Combined autologous platelet-rich plasma with microneedling verses microneedling with distilled water in the treatment of atrophic acne scars: A concurrent split-face study. *Journal of Cosmetic Dermatology*, *15*, 434–443.

Aust, M. C., Fernandes, D., Kolokythas, P., Kaplan, H. M., & Vogt, P. M. (2008). Percutaneous collagen induction therapy: An alternative treatment for scars, wrinkles, and skin laxity. *Plastic and Reconstructive Surgery*, *121*, 1421–1429.

Aust, M. C., Reimers, K., Gohritz, A., Jahn, S., Stahl, F., Repenning, C., … Vogt, P. M. (2010). Percutaneous collagen induction. Scarless skin rejuvenation: Fact or fiction? *Clinical and Experimental Dermatology*, *35*, 437–439.

Badran, M., Kuntsche, J., & Fahr, A. (2009). Skin penetration enhancement by a microneedle device (Dermaroller) in vitro: Dependency on needle size and applied formulation. *European Journal of Pharmaceutical Sciences*, *36*, 511–523.

Bandyopadhyay, B., Fan, J., Guan, S., Li, Y., Chen, M., Woodley, D. T., & Li, W. A. (2006). "Traffic control" role for TGFbeta3: Orchestrating dermal and epidermal cell motility during wound healing. *J. Cell Biology*, *172*, 1093–1105.

Budamakuntla, L., Loganathan, E., Suresh, D. H., Shanmugam, S., Suryanarayan, S., & Dongare, A. (2013). A randomised, open-label, comparative study of tranexamic acid microinjections and tranexamic acid with microneedling in patients with melasma. *Journal of Cutaneous and Aesthetic Surgery*, *6*, 139–143.

Buganza, A., & Kuhl, E. (2013). Systems-based approaches toward wound healing. *Pediatric Research*, *73*, 553–563.

Chawla, S. (2014). Split face comparative study of microneedling with PRP versus microneedling with vitamin C in treating atrophic post acne scars. *Journal of Cutaneous and Aesthetic Surgery*, *7*, 209–212.

Demidova-Rice, T. N., Hamblin, M. R., & Herman, I. M. (2012). Acute and impaired wound healing: Pathophysiology and current methods for drug delivery, part 1: Normal and chronic wounds: Biology, causes and approaches to care. *Advances in Skin & Wound Care*, *25*, 304–314.

Dhurat, R., & Mathapati, S. (2015). Response to microneedling treatment in men with androgenetic alopecia who failed to respond to conventional therapy. *Indian Journal of Dermatology*, *60*, 260–264.

Dhurat, R., Sukesh, M., Avhad, G., Dandale, A., Pal, A., & Pund, P. A. (2013). Randomized evaluator blinded study of effect of microneedling in androgenetic alopecia: A pilot study. *Int J Trichology*, *5*, 6–11.

Dogra, S., Yadav, S., & Sarangal, R. (2014). Microneedling for acne scars in Asian skin type: An effective low cost treatment modality. *Journal of Cosmetic Dermatology*, *13*, 180–187.

El-Domyati, M., Barakat, M., Awad, S., Medhat, W., El Fakahany, H., & Farag, H. (2015a). Multiple microneedling sessions for minimally invasive facial rejuvenation: An objective assessment. *International Journal of Dermatology*, *54*, 1361–1369.

El-Domyati, M., Barakat, M., Awad, S., Medhat, W., El-Fakahany, H., & Farag, H. (2015b). Microneedling therapy for atrophic acne scars an objective evaluation. *The Journal of Clinical and Aesthetic Dermatology*, *8*, 36–42.

Fabrocini, G., DeVita, V., & Pastore, F. (2012). Collagen induction therapy for the treatment of upper lip wrinkles. *Journal of Dermatological Treatment*, *23*, 144–152.

Ferguson, M. W., & Kane, O. S., (2004). Scar-free healing: From embryonic mechanisms to adult therapeutic intervention. *Philosophical Transactions of the Royal Society of London. Series B, Biological Sciences*, *359*, 839–850.

Fernandes, D. (2005). Minimally invasive percutaneous collagen induction. *Oral and Maxillofacial Surgery Clinics of North America*, *17*, 51–63.

Fernandes, D., & Signorini, M. (2008). Combating photoaging with percutaneous collagen induction. *Clinics in Dermatology*, *26*, 192–199.

Gabbiani, G. (2003). The myofibroblast in wound healing and fibrocontractive diseases. *The Journal of Pathology*, *200*, 500–503.

Greaves, N. S., Ashcroft, K. J., Baguneid, M., & Bayat, A. (2013). Current understanding of molecular and cellular mechanisms in fibroplasia and angiogenesis during acute wound healing. *Journal of Dermatological Science*, *72*, 206–217.

Gupta, A. K., Carviel, J., & Abramovits, W. (2017). Treating alopecia areata: Current practices versus new directions. *American Journal of Clinical Dermatology*, *18*, 67–75.

Kajdaniuk, D., Marek, B., Foltyn, W., & Kos-Kudła, B. (2011). Naczyniowo-śródbłonkowy czynnik wzrostu (VEGF) w endokrynologii i onkologii. *Endokrynologia Polska*, *62*, 456–464.

Khater, M. H., Khattab, F. M., & Abdelhaleem, M. R. (2016). Treatment of striae distensae with needling therapy versus CO_2 fractional laser. *Journal of Cosmetic and Laser Therapy*, *18*, 75–79.

Kim, J. H., Park, H. Y., Jung, M., & Choi, E. H. (2012). Automicroneedle therapy system combined with topical tretinoin shows better regenerative effects compared with each individual treatment. *Clinical and Experimental Dermatology*, *38*, 57–65.

Koca, K. A., Cecen, D., Gurgen, S. G., Sayin, O., & Cetin, F. (2013). A comparison study of growth factor expression following treatment with transcutaneous electrical nerve stimulation, saline solution, povidone-iodine, and lavender oil in wounds healing. *Evidence-based Complementary and Alternative Medicine*, *2013*, 361832.

Konda, D., & Thappa, D. M. (2013). Mesotherapy: What is new? *Indian Journal of Dermatology, Venereology and Leprology*, *79*, 127–134.

Kontochristopoulos, G., Kouris, A., Platsidaki, E., Markantoni, V., Gerodimou, M., & Antoniou, C. (2016). Combination of microneedling and 10% trichloroacetic acid peels in the management of infraorbital dark circles. *Journal of Cosmetic and Laser Therapy*, *18*, 289–292.

Korobko, I. V., & Lomonosov, K. M. (2016). A pilot comparative study of topical latanoprost and tacrolimus in combination with narrow-band ultraviolet B phototherapy and microneedling for the treatment of nonsegmental vitiligo. *Dermatologic Therapy*, *29*, 437–441.

Laws, R. A., Finley, E. M., McCollough, M. L., & Grabski, W. J. (2012). Alabaster skin after carbon dioxide laser resurfacing with histologic correlation. *Dermatologic Surgery*, *26*, 137–140.

Lee, H. J., Lee, E. G., Kang, S., Sung, J. H., Chung, H. M., & Kim, D. H. (2014). Efficacy of microneedling plus human stem cell conditioned medium for skin rejuvenation: A randomized, controlled, blinded split face study. *Annals of Dermatology*, *26*, 584–591.

Liebl, H., & Kloth, L. C. (2012). Skin cell proliferation stimulated by microneedles. *The Journal of the American College of Certified Wound Specialists*, *4*, 2–6.

Lima, E. A. (2015). Microneedling in facial recalcitrant melasma: Report of a series of 22 cases. *Anais Brasileiros de Dermatologia*, *90*, 919–921.

Lima, E. A., Lima, M. M. D. A., Paixão, M. P., & Miot, H. A. (2017). Assessment of the effects of skin microneedling as adjuvant therapy for facial melasma: A pilot study. *BMC Dermatology*, *28*, 14.

McCrudden, M. T., McAlister, E., Courtenay, A. J., González-Vázquez, P., Singh, T. R., & Donnelly, R. F. (2015). Microneedle applications in improving skin appearance. *Experimental Dermatology*, *24*, 561–566.

McDougall, S., Dallon, J., Sherratt, J., & Maini, P. (2006). Fibroblast migration and collagen deposition during dermal wound healing: Mathematical modelling and clinical implications. *Philosophical Transactions. Series A, Mathematical, Physical, and Engineering Sciences*, *364*, 1385–1405.

Mina, M., Elgarhy, L., Al-Saeid, H., & Ibrahim, Z. (2018). Comparison between the efficacy of microneedling combined with 5-fluorouracil vs microneedling with tacrolimus in the treatment of vitiligo. *Journal of Cosmetic Dermatology*, 1473–2165. https://doi.org/10.1111/jocd.12440

Nair, P. A., & Arora, T. H. (2014). Microneedling using dermaroller: A means of collagen induction therapy. *Gujarat Medical Journal*, *69*, 24–27.

Nassar, A., Ghorney, S., El-Gohary, Y., & El-Desoky, F. (2016). Treatment of striae distensae with needling therapy versus microdermabrasion with sonophoresis. *Journal of Cosmetic and Laser Therapy*, *18*, 330–334.

Rawlins, J. M. (2006). Quantifying collagen type in mature burn scars: A novel approach using histology and digital image analysis. *Journal of Burn Care & Research*, *27*, 60–65.

Ross, E. V., Naseef, G. S., McKinlay, J. R., Barnette, D. J., Skrobal, M., Grevelink, J., & Anderson, R. R. (2000). Comparison of carbon dioxide laser, erbium: YAG laser, dermabrasion, and dermatome: A study of thermal damage, wound contraction, and wound healing in a live pig model: Implications for skin resurfacing. *The Journal of the American Academy of Dermatology*, *42*, 92–105.

Sahni, K., & Kassir, M. (2013). Dermafrac™: An innovative new treatment for periorbital melanosis in a dark-skinned male patient. *Journal of Cutaneous and Aesthetic Surgery*, *6*, 158–160.

Sarkar, R., Garg, V. K., & Mysore, V. (2011). Position paper on mesotherapy. *Indian Journal of Dermatology, Venereology and Leprology*, *77*, 232–237.

Seo, K. Y., Kim, D. H., Lee, S. E., Yoon, M. S., & Lee, H. J. (2013). Skin rejuvenation by microneedle fractional radiofrequency and a human stem cell conditioned medium in Asian skin. A randomized controlled investigator blinded split face study. *Journal of Cosmetic and Laser Therapy*, *15*, 25–33.

Shah, K. B., Shah, A. N., Solanki, R. B., & Raval, R. C. A. (2017). Comparative study of microneedling with platelet-rich plasma plus topical Minoxidil (5%) and topical Minoxidil (5%) alone in androgenetic alopecia. *The International Journal of Trichology*, *9*, 14–18.

Sharad, J. (2011). Combination of microneedling and glycolic acid peels for the treatment of acne scars in dark skin. *Journal of Cosmetic Dermatology*, *10*, 317–323.

Singh, A., & Yadav, S. (2016). Microneedling: Advances and widening horizons. *Indian Dermatology Online Journal*, *7*, 244–254.

Šuca, H., Zajiček, R., & Vodsloň, Z. (2017). Microneedling – A form of collagen induction therapy – Our first experiences. *Acta Chirurgiae Plasticae*, *59*, 33–36.

Yadav, S., & Dogra, S. A. (2016). Cutaneous reaction to microneedling for Postacne scarring caused by nickel hypersensitivity. *Aesthetic Surgery Journal*, *36*, NP168–NP170.

Zeitter, S., Sikora, Z., Jahn, S., Stahl, F., Strauß, S., Lazaridis, A., … Aust, M. C. (2014). Microneedling: Matching the results of medical needling and repetitive treatments to maximize potential for skin regeneration. *Burns*, *40*, 966–973.

How to cite this article: Zduńska K, Kołodziejczak A, Rotsztejn H. Is skin microneedling a good alternative method of various skin defects removal. *Dermatologic Therapy*. 2018; e12714. https://doi.org/10.1111/dth.12714

Review Article

Skin Pharmacology and Physiology

Skin Pharmacol Physiol 2018;31:332–336
DOI: 10.1159/000491755

Received: February 22, 2018
Accepted after revision: July 2, 2018
Published online: September 20, 2018

Antioxidant Properties of Ferulic Acid and Its Possible Application

Kamila Zduńska Agnieszka Dana Anna Kolodziejczak Helena Rotsztejn

Chair of Cosmetology, Department of Cosmetology and Aesthetic Dermatology, Faculty of Pharmacy, Medical University of Łódź, Łódź, Poland

Keywords
Ferulic acid antioxidant · Photoaging

Abstract
Ferulic acid has low toxicity and possesses many physiological functions (anti-inflammatory, antioxidant, antimicrobial activity, anticancer, and antidiabetic effect). It has been widely used in the pharmaceutical, food, and cosmetics industry. Ferulic acid is a free radical scavenger, but also an inhibitor of enzymes that catalyze free radical generation and an enhancer of scavenger enzyme activity. Ferulic acid has a protective role for the main skin structures: keratinocytes, fibroblasts, collagen, elastin. It inhibits melanogenesis, enhances angiogenesis, and accelerates wound healing. It is widely applied in skin care formulations as a photoprotective agent, delayer of skin photoaging processes, and brightening component. Nonetheless, its use is limited by its tendency to be rapidly oxidized. © 2018 S. Karger AG, Basel

Introduction

Properties of Ferulic Acid

Ferulic acid ([E]-3-[4-hydroxy-3-methoxy-phenyl] prop-2-enoic acid) (Fig. 1) belongs to the phenolic acid group commonly found in plant tissues [1]. Phenolic acids are secondary metabolites of varying chemical structures and biological properties. The plants are mainly found in bound form as ester or glycosides, lignin components, and hydrolysis tannins [2, 3]. In terms of chemical structure, they can be divided into derivatives of cinnamic and benzoic acid, varying in number and substitution of hydroxyl and methoxy groups, and phenolic acids of unusual character. An additional group is the depside, which is a combination of two or more phenolic acids [2]. Ferulic acid, like caffeic, p-coumaric, synapine, syryte, and vanillin acids, is the most common cinnamic acid derivative [3].

Ferulic acid is most commonly found in whole grains, spinach, parsley, grapes, rhubarb, and cereal seeds, mainly wheat, oats, rye, and barley (Table 1). One of the most important role of phenolic acids, especially cinnamic acid derivatives, is their antioxidant activity, which depends primarily on the number of hydroxyl and methoxy groups attached to the phenyl ring [3, 4]. Ferulic acid is more easily absorbed into the body and stays in the blood longer than any other phenolic acids. Ferulic acid is considered to be a superior antioxidant [5]. Ferulic acid has low toxicity and possesses many physiological functions, including anti-inflammatory, antimicrobial, anticancer (for instance lung, breast, colon and skin cancer), anti-arrhythmic, and antithrombotic activity, and it also demonstrated antidiabetic effects and immunostimulant properties, and it reduces nerve cell damage and may help

KARGER
© 2018 S. Karger AG, Basel
E-Mail karger@karger.com
www.karger.com/spp

Kamila Zduńska
Department of Cosmetology and Aesthetic Dermatology, Faculty of Pharmacy
Medical University of Łódź, Muszyńskiego 1 Street
PL–91-151 Łódź (Poland)
E-Mail kamila.zdunska@stud.umed.lodz.pl

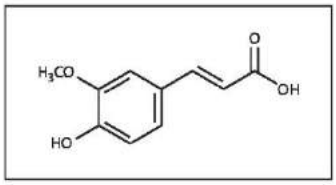

Fig. 1. Chemical structure of ferulic acid.

Table 1. Average ferulic acid content in plant-delivered foods

Foods	Ferulic acid content, mg\kg (in liquid mg/dm^3)
Black currant	15
Black berry	10
Spinach	110
Tomatoes	700
Cucurbit	220
Wheat flour	150
Wheat bran	700
Oatmeal	145

to repair damaged cells. Furthermore, it is a sports supplement because it can neutralize free radicals in muscle tissue (alleviate muscle fatigue). It has been widely used in pharmaceutics and food. Moreover, it is widely applied in skin care formulations as a photoprotective agent (sunscreens), delayer of skin photoaging processes, and brightening component. Nonetheless, its use is limited by its tendency to be rapidly oxidized [3, 5–7].

Antioxidative Activity of Ferulic Acid

The antioxidant action mechanism of ferulic acid is complex, mainly based on the inhibition of the formation of reactive oxygen species (ROS) or nitrogen, but also the neutralization ("sweeping") of free radicals. In addition, this acid is responsible for chelating protonated metal ions, such as Cu(II) or Fe(II) [8, 9]. Ferulic acid is not only a free radical scavenger, but also an inhibitor of enzymes that catalyze free radical generation and an enhancer of scavenger enzyme activity. It is directly related to its chemical structure [3, 10–12]. Its antioxidating properties are primarily related to scavenging of free radicals, binding transition metals such as iron and copper, and lipid peroxidation prevention. The mechanism of antioxidative activity of ferulic acid is the ability to form stable phenoxyl radicals, by the reaction of the radical molecule with the molecule of antioxidant. This makes it difficult to initiate a complex reaction cascade leading to the generation of free radicals. This compound may also act as hydrogen donor, giving atoms directly to the radicals. This is particularly important for the protection of cell membrane lipid acids, from undesired autoxidation processes. As a secondary antioxidant, ferulic acids and their related compounds are able to bind transition metals such as iron and copper [13]. This prevents the formation of toxic hydroxyl radicals, which lead to cell membrane peroxidation [14].

Free radicals may also be formed through natural human physiological processes, such as cell respiration process. These reactions are catalyzed by some enzymes, among others xanthine oxidase and cyclooxygenase-2 [15]. It is suggested that inhibition of this enzyme could prevent the changes caused by oxidative stress, including photophobia [16]. Literature data report high efficacy of ferulic acid and its derivatives in reducing xanthine oxidase and cyclooxygenase activity. It is therefore believed that ferulic acid reduces the amount of ROS produced by the enzyme-catalyzed transformation [17].

Ferulic Acid as an Antioxidant against Negative UV Influence

Highly exposed to UV-induced oxidative stress are keratinocytes and fibroblasts. ROS damage cells by the process of lipid peroxidation, amino acid nitration, and even DNA alterations, leading to cell death. Ferulic acid exhibits protective antioxidant properties, relative to various skin structures and skin cells. Pluemsamran and partners [18] proved that human endothelial cells and keratinocytes are much less susceptible to UVA-induced free radical damage when exposed to ferulic acid prior to irradiation. It is believed that fibroblasts are exposed to UVA, and the oxidative stress associated with it is greater than that of the more superficially exposed keratinocytes. The human fibroblast test showed that ferulic acid, administered prior to exposure to UVA radiation, significantly reduced its adverse effects. It prevents UV-induced cell cycle alterations and DNA damage and regulates the expression of DNA repair genes. Hahn and partners [19] have shown that intracellular ROS production is nearly 2-fold lower in fibroblasts, which after irradiation with UVA, have ferulic acid applied. Similar effects, in the form of protection against free radical damage, have been observed in UVB-exposed fibroblasts. In their research, Ambothi and Nagarajan [20] demonstrated the protective role of ferulic acid applied to cells 30 min prior to exposure to UVB. Compared to non-antioxidant-exposed cells, cytotoxicity, lipid

Skin Pharmacol Physiol 2018;31:332–336
DOI: 10.1159/000491755

peroxidation, DNA alteration, antioxidant enzyme decline, and reduced ROS production have been observed. As UVB-induced ROS are one of the factors contributing significantly to the development of skin cancer, ferulic acid, which is known to lower their levels, has been found to be a promising anticancer substance [20]. In another study on human fibroblasts, ferulic acid proved to be an effective substance that protects heat shock proteins from degradation caused by hydrogen peroxide. As a result, the cell-treated assay, prior to UV irradiation, showed significantly greater cell survival and less ROS-induced damage. It has been proven to be closely related to significantly increased levels of protective heat shock proteins compared to the ferulic acid trial [21].

The activation of MMP-2 and MMP-9 under the influence of UVB radiation leads to photosaturation and initiation of photocancerogenesis processes [22]. Staniforth et al. [23] have proven that these processes are effectively prevented by the application of ferulic acid, just after exposure to UVB radiation. Studies conducted on mice showed a decrease in MMP-2 and MMP-9 activity by 37 and 83%, respectively, compared to the non-antioxidant-exposed group [23]. Ferulic acid administered before irradiation causes reduced cytotoxicity, less stimulation of MMP-1 matrix metalloproteinases, and the generation of ROS, compared to those exposed without antioxidant. Also, the level of endogenous antioxidants, glutathione and catalase, declined less and restored faster in the probe with ferulic acid. The antioxidant tested proved to be effective not only for its free radical scavenging capacity but also for its protective effect on the intracellular antioxidant system [18]. Bian and partners [24] have demonstrated a high efficacy of ferulic acid in the prevention of H_2O_2-induced damage in human embryonic kidney cells. Ferulic acid application, before exposure to H_2O_2, increased cell survival and antioxidant enzyme levels (catalase, superoxide dismutase). It has been stated that natural antioxidants such as ferulic acid can prevent adverse changes in the body resulting from oxidative stress, including collagen degradation [24].

Kawaguchi et al. [25] in their study on human fibroblasts showed that the main cause of elastosis (accumulation of tropoelastin aggregates in skin reticular layer) are free oxygen radicals. In the cells exposed to ROS, a significant increase in tropoelastin mRNA expression was observed. This process was reduced when the fibroblasts were treated with catalase referred to as free radical scavengers. On this basis, the authors suggest that the use of antioxidants such as ferulic acid could prevent the unfavorable elastosis phenomenon [25, 26].

Angiogenesis Effect

In light of current knowledge, ferulic acid is believed to have an angiogenesis effect by affecting the activity of the main factors involved in it, i.e., vascular endothelial growth factor (VEGF), platelet derived growth factor (PDGF), and hypoxia-inducible factor 1 (HIF-1). Lin and partners [27] in their research conducted using human umbilical vein endothelial cells have shown that ferulic acid enhances VEGF and PDGF expression and increases the amount of hypoxia induced HIF-1, which generates hypoxia-responsive responses. The authors believe that ferulic acid is an effective substance that promotes the formation of new vessels, as evidenced in both in vivo and in vitro studies [27, 28].

Regeneration and Wound Healing Effect

The experiment conducted with the use of diabetic rats demonstrated that ferulic acid accelerates the regeneration and healing of wounds. The wound contraction percentage in rats to whom ferulic acid ointment was given was 27% after 4 days, while in the group which did not receive it, only 14% was administered after 4 days. After 16 days, rats treated with ferulic acid were almost completely healed (96%). In a control group that used an ointment with 1% soframycin, standardized for treatment of difficult-to-heal wounds, the wound was healed in 83% after 16 days. There was also a faster onset of granulomas in the ferulic acid group and faster epithelialization compared to the control group [29]. Ghaisas and partners [30], in a similar study, in addition to faster shrinking of the wound and increased epithelialization, observed an increased hydroxyproline and hydroxylysine synthesis (major amino acids involved in wound healing, which are the precursors of collagen), in the skin of diabetic rats to whom ferulic acid was given. Moreover, it has been shown that the use of ferulic acid ointment during healing inhibits lipid peroxidation and increases catalase, superoxide dismutase, and glutathione. The authors suggest that this phenomenon also significantly accelerates shrinkage of the wound [30].

The Use of Ferulic Acid in Cosmetology and Aesthetic Dermatology

Prevention of skin aging processes is one of the main issues in contemporary cosmetology and aesthetic medicine. Protection against the effects of external factors such as UV radiation, air pollution, and free radical scavenging plays an important role. The compounds with proven antioxidative efficacy include ferulic acid. Initially, it was used in cosmetics as a stabilizer of other commonly known

antioxidants such as vitamin C and vitamin E. Research shows, though, that this compound is not only used as an additional compound, but also an active ingredient with antioxidative properties, which supports intracellular antioxidant defense systems. Thanks to this, ferulic acid has a protective role for the main skin structures (keratinocytes, fibroblasts, collagen, elastin), which is used in anti-aging cosmetic formulations. Due to its ability to inhibit the main enzyme of melanogenesis (tyrosinase), it is also used in anti-blemish cosmetic formulations.

Ferulic acid is used in skin-lightening preparations because it inhibits tyrosinase activity (an enzyme involved in melanogenesis) and inhibits melanocytic proliferation [31, 32]. Staniforth et al. [23] noted that ferulic acid absorbs UV (290–320 nm). In order to increase the lightening effect, ferulic acid can be combined with other compounds that also have a brightening effect, but by other processes such as niacinamide (inhibits the movement of melanosomes from melanocytes to keratinocytes). Saint-Leger et al. [33] reported better effects of ferulic acid after adding to it a keratolytic agent such as lipohydroxycarbones.

Ferulic acid is widely applied in skin care formulations as a delayer of skin photoaging processes and photoprotective agent. Its application as a topical antioxidant has become an important administration route due to maintaining a high local concentration and the low cutaneous metabolism [3]. Moreover, local ferulic acid penetrates deeply into the skin, both acidic and neutral pH, in dissociated and non-dissociated form [34]. Saija et al. [35] studied the penetration of ferulic and caffeic acid soluble in saturated aqueous solutions (pH 3 and pH 7.2) by a human skin cut in the Franz cells. It turned out that these acids, regardless of pH, penetrated the stratum corneum. It was noted that ferulic acid has a slightly better penetration capacity, which was explained by the known higher lipophilicity of this acid. Research on phenolic antioxidants has shown that ferulic acid improves the chemical stability of L-ascorbic acid and α-tocopherol preparations, thereby increasing its photoprotection properties.

Ferulic acid is used in the production of face masks, as well as antioxidant, protective, and moisturizing creams/lotions. The recommended acid concentration in cosmetic products of this type is from 0.5 to 1%. Ferulic acid is also used in medical cosmetology and aesthetics salons. It is most often used at a concentration of 12% and in combination with vitamins C and hyaluronic acid. Ferulic acid is used in the following procedures: microneedling and non-needle mesotherapy, chemical peels, and grooming treatments. Indications for the use of ferulic acid include skin aging and photoaging, hyperpigmentation (melasma), seborrheic skin, and acne.

Conclusion

Research conducted so far has shown that ferulic acid has strong antioxidant properties, which is directly involved with its protective role to cellular structures and inhibition of melanogenesis. It is increasingly used in cosmetic preparations, mainly to inhibit photostage. At the same time, it helps to reduce fine wrinkles and existing discoloration. Good penetration into the skin, compatibility with many cosmetic formulas, and stabilizing properties of other ingredients make ferulic acid an increasingly used compound in cosmetology.

Acknowledgements

This work was supported by statutory research activity of the Department of Cosmetology and Aesthetic Dermatology, Faculty of Pharmacy, Medical University of Lodz, No. 503/3-066-01/503-31-001.

Disclosure Statement

The authors declare no conflict of interest.

References

1 Mattila P, Kumpulainen J: Determination of free and total phenolic acids in plant-derived foods by HPLC with diode-array detection. J Agric Food Chem 2002;50:3660–3667.
2 Parus A: Przeciwutleniające i farmakologiczne właściwości kwasów fenolowych. Post Fitoter 2013;1:48–53.
3 Bezerra G, Pereira M, Ostrosky E, Barbosa E, Moura M, Ferrari M, Aragão C, Gomes A: Compatibility study between ferulic acid and excipients used in cosmetic formulations by TG/DTG, DSC and FTIR. J Therm Anal Calorim 2017;127:1683–1691.
4 Aguilar-Hernández I, Afseth NK, López-Luke T, Contreras-Torres F, Wold JP, Ornelas-Soto N: Surface enhanced Raman spectroscopy of phenolic antioxidants: a systematic evaluation of ferulic acid, p-coumaric acid, caffeic acid and sinapic acid. Vib Spectrosc 2017;89:113–122.

5 Tee-ngam P, Nunant N, Rattanarat P, Siangproh W, Chailapakul O: Simple and rapid determination of ferulic acid levels in food and cosmetic samples using paper-based platforms. Sensors 2013;13:13039–13053.
6 Cota-Arriola O, Plascencia-Jatomea M, Lizardi-Mendoza J, Robles-Sánchez RM, Ezquerra-Brauer JM, Ruíz-García J, Vega-Acosta JR, Cortez-Rocha MO: Preparation of chitosan matrices with ferulic acid: physicochemical characterization and relationship on the growth of *Aspergillus parasiticus*. Journal of Food 2017;15:65–74.
7 Moldovan M, Lahmar A, Bogdan C, Pătrăuan S, Tomuță I, Crișan M: Formulation and evaluation of a water-in-oil cream containing herbal active ingredients and ferulic acid. Cluj Med 2017;90:212–219.
8 Rice-Evans CA, Miller NJ, Paganga G: Structure-antioxidant activity relationships of flavonoids and phenolic acids. Free Rad Biol Med 1996;20:933–956.
9 Rice-Evans CA, Miller NJ, Paganga G: Antioxidant properties of phenolic compounds. Trends Plant Sci 1997;2:152–159.
10 Lodovici M, Guglielmi F, Meoni M, Dolara P: Effect of natural phenolic acids on DNA oxidation in vitro. Food Chem Toxicol 2001;39:1205–1210.
11 Masella R, Vari R, d'Archivio M, di Benedetto R, Matarrese P, Malorni W, Scazzocchio B, Giovannini C: Extra virgin olive oil biophenols inhibit cell-mediated oxidation of LDL by increasing the mRNA transcription of glutathione-related enzymes. J Nutr 2004;134:785–791.
12 Masella R, Cantafora A, Modesti D, Cardilli A, Gennaro L, Bocca A, Coni E: Antioxidant activity of 3,4-DHPEA-EA and protocatechuic acid: a comparative assessment with other olive oil biophenols. Redox Rep 1999;4:113–121.
13 Kiewlicz J, Szymusiak H, Zieliński R: Symthesis. Thermal stability and antioxidant activity of long-chain alkyl esters od ferulic acid. Zywn Nauk Technol Ja 2015;4:188–200.
14 Scharffetter-Kochanek K, Brenneisen P, Wenk J, Herrmann G, Ma W, Kuhr L: Photoaging of the skin from phenotype to mechanisms. Exp Gerontol 2000;35:307–316.
15 Sheu S, Nauduri D, Anders MW: Targeting antioxidants to mitochondria: a new therapeutic direction. Biochim Biophys Acta 2006;1762:256–265.
16 Higgins P, Dawson J, Walters M: The potential for xanthine oxidase inhibition in the prevention and treatment of cardiovascular and cerebrovascular disease. Cardiovasc Psychiatry Neurol 2009;2009:1–9.
17 Nile SH, Ko EY, Kim DH, Keum YS: Screening of ferulic acid related compounds as inhibitors of xanthine oxidase and cyclooxygenase-2 with anti-inflammatory activity. Rev Bras Farmacogn 2016;26:50–55.
18 Pluemsamran T, Onkoksoong T, Panich U: Caffeic acid and ferulic acid inhibit UVA-induced matrix metalloproteinase-1 through regulation of antioxidant defense system in keratinocyte HaCaT cells. Photochem Photobiol 2012;88:961–968.
19 Hahn HJ, Kim KB, Bae S, Choi BG, An S, Ahn KJ, Kim SJ: Pretreatment of ferulic acid protects human dermal fibroblasts against ultraviolet A irradiation. Ann Dermatol 2016;28:740–748.
20 Ambothi K, Nagarajan RP: Ferulic acid prevents ultraviolet-B radiation induced oxidative DNA damage in human dermal fibroblasts. Int J Nutr Pharmacol Neurol Dis 2014;4:203–213.
21 Calabrese V, Calafato S, Puleo E, Cornelius C, Sapienza M, Morganti P, Mancuso C: Redox regulation of cellular stress response by ferulic acid ethyl ester in human dermal fibroblasts: role of vitagenes. Clin Dermatol 2008;26:s.358–s.363.
22 Inomata S, Matsunaga Y, Amano S, Takada K, Kobayashi K, Tsunenaga M: Possible involvement of gelatinases in basement membrane damage and wrinkle formation in chronically ultraviolet B-exposed hairless mouse. J Invest Dermatol 2003;120:128–134.
23 Staniforth V, Huang W, Aravindaram K, Yang N: Ferulic acid, a phenolic phytochemical, inhibits UVB-induced matrix metalloproteinases in mouse skin via posttranslational mechanisms. J Nutr Biochem 2012;23:443–451.
24 Bian Y, Guo J, Majeed H, Zhu K, Guo X, Peng W, Zhou H: Ferulic acid renders protection to HEK293 cells against oxidative damage and apoptosis induced by hydrogen peroxide. In Vitro Cell Dev Biol Anim 2015;51:722–729.
25 Kawaguchi Y, Tanaka H, Okada T, Konishi H, Takahashi M, Ito M, Asai J: Effect of reactive oxygen species on the elastin mRNA expression in cultured human dermal fibroblasts. Free Radic Biol Med 1997;23:162–165.
26 Warren R, Gartstein V, Kligman AM, Montagna W, Allendorf RA, Ridder GM: Age, sunlight, and facial skin: a histologic and quantitative study. J Am Acad Dermatol 1991;25:751–760.
27 Lin C, Chiu J, Wu I, Wang B, Pan C, Chen Y: Ferulic acid augments angiogenesis via VEGF, PDGF and HIF-1 alpha. J Nutr Biochem 2010;21:627–633.
28 Yang G, Jiang J, Lu W: Ferulic acid exerts anti-angiogenic and anti-tumor activity by targeting fibroblast growth factor receptor 1-mediated angiogenesis. Int J Mol Sci 2015;16:24011–24031.
29 Sangeeta D, Digvijay S, Pradeep TD, Rupesh S, Rahul T: Healing potential of ferulic acid on dermal wound in diabetic animals. Asian J Molec Model 2015;1:1–16.
30 Ghaisas M, Kshirsagar S, Sahane R: Evaluation of wound healing activity of ferulic acid in diabetic rats. Int Wound J 2014;11:523–532.
31 Oresajo C, Stephens T, Hino PD: Protective effects of a topical antioxidant mixture containing vitamin C, ferulic acid, and phloretin against ultraviolet-induced photodamage in human skin. J Cosmet Dermatol 2008;7:290–297.
32 Murray JC, Burch JA, Streilein RD, Iannacchione MA, Hall RP, Pinnell SR: A topical antioxidant solution containing vitamins C and E stabilized by ferulic acid provides protection for human skin against damage caused by ultraviolet irradiation. J Am Acad Dermatol 2008;59:418–425.
33 Saint-Leger D, Leveque JL, Verschoore M: The use of hydroxy acids on the skin: characteristics of C8-lipohydroxy acid. J Cosmet Dermatol 2007;6:59–65.
34 Saija A, Tomaino A, Lo Cascio R, Trombetta D, Proteggente A, De Pasquale A, Uccella N, Bonina F: Ferulic and caffeic acids as potential protective agents against photooxidative skin damage. J Sci Food Agric 1999;79:476–480.
35 Saija A, Tomaino A, Lo Cascio R, Trombetta D, Proteggente A, De Pasquale A, Uccella N, Bonina F: In vitro and in vivo evaluation of caffeic and ferulic acids as topical photoprotective agents. Int J Pharm 2000;1:39–47.